

DEVELOPMENT OF A CLINICAL INSTRUCTIONAL MODULE BASED ON  
CURRENT PRESCRIBING TRENDS FOR COMMON ANTERIOR SEGMENT  
DIAGNOSES

by

Chelsea Faith Richards

Anne Marie St. Louis

This paper is submitted in partial fulfillment of the requirements for the degree of

Doctor of Optometry

Ferris State University

Michigan College of Optometry

May, 2013

DEVELOPMENT OF A CLINICAL INSTRUCTIONAL MODULE BASED ON  
CURRENT PRESCRIBING TRENDS FOR COMMON ANTERIOR SEGMENT  
DIAGNOSES

by

Chelsea Faith Richards

Anne Marie St. Louis

Has been approved

May, 2013

APPROVED:

, Faculty Advisor

Ferris State University  
Doctor of Optometry Senior Paper  
Library Approval and Release

DEVELOPMENT OF A CLINICAL INSTRUCTIONAL MODULE BASED ON  
CURRENT PRESCRIBING TRENDS FOR COMMON ANTERIOR SEGMENT  
DIAGNOSES

I, Chelsea Faith Richards, hereby release this paper as described above to Ferris State University with the understanding that it will be accessible to the general public. This release is required under the provisions of the Federal Privacy Act.

Doctoral Candidate

03-20-13

---

Date

Ferris State University  
Doctor of Optometry Senior Paper  
Library Approval and Release

DEVELOPMENT OF A CLINICAL INSTRUCTIONAL MODULE BASED ON  
CURRENT PRESCRIBING TRENDS FOR COMMON ANTERIOR SEGMENT  
DIAGNOSES

I, Anne Marie St. Louis, hereby release this paper as described above to Ferris State University with the understanding that it will be accessible to the general public. This release is required under the provisions of the Federal Privacy Act.



## ABSTRACT

*Background:* The pharmaceutical industry is constantly developing new therapeutic agents to aid in the efficacious treatment of ophthalmic disorders. This ever-evolving landscape adds a level of complexity to optometric practice and education that may be addressed by the utilization of a clinical instructional module. The purpose of this research is to obtain survey data regarding current prescribing patterns of practicing optometrists for the treatment of eight common anterior segment diagnoses. The data acquired from the survey were combined with a comprehensive literature review and used to develop an instructional module aimed at increasing student familiarity with prescribing commonly utilized treatment regimens. *Methods:* An electronic web-based survey was distributed to approximately 750 members of the Michigan Optometric Association. The survey addressed eight common anterior segment diagnoses including moderate dry eye, adenoviral conjunctivitis, bacterial conjunctivitis, corneal metallic foreign body, bacterial corneal ulcer, mild anterior uveitis, epithelial basement membrane dystrophy (EBMD, Cogan's, Map-Dot-Fingerprint Dystrophy), and mild seasonal allergic conjunctivitis. The survey provided a number of treatment options, all of which were prudent treatments, and asked that the clinician choose which treatment option(s)

they would ideally choose to prescribe for each diagnosis. *Results:* There were eighty-nine respondents to the survey. The survey data were analyzed for overall trends, and an instructional module was developed in the form of a sample prescription pad.

*Conclusions:* Optometrists employ a variety of methods to treat common anterior segment disorders, but trends were established for each of the diagnoses addressed in the survey. A literature review confirmed the validity of the treatment options selected by respondents.

## TABLE OF CONTENTS

	Page
LIST OF TABLES.....	vi
LIST OF FIGURES.....	vii
INTRODUCTION.....	1
METHODS.....	3
RESULTS.....	5
INSTRUCTIONAL MODULE 1: MODERATE DRY EYE.....	8
INSTRUCTIONAL MODULE 2: ADENOVIRAL CONJUNCTIVITIS.....	17
INSTRUCTIONAL MODULE 3: BACTERIAL CONJUNCTIVITIS.....	24
INSTRUCTIONAL MODULE 4: CORNEAL METALLIC FOREIGN BODY.....	29
INSTRUCTIONAL MODULE 5: BACTERIAL CORNEAL ULCER.....	36
INSTRUCTIONAL MODULE 6: SEASONAL ALLERGIC CONJUNCTIVITIS.....	41
INSTRUCTIONAL MODULE 7: MILD ANTERIOR UVEITIS.....	47
INSTRUCTIONAL MODULE 8: EBMD.....	52
CONCLUSION.....	56

LIST OF TABLES

Table	Page
1. Demographics of Respondents.....	7

## LIST OF FIGURES

Figure	Page
1. Demographics of Respondents: Number of Male versus Female Respondents.....	5
2. Demographics of Respondents: Number per Age Group.....	5
3. Demographics of Respondents: Number by Years in Practice.....	6
4. Demographics of Respondents: Number by Mode of Practice.....	6
5. Moderate Dry Eye: Treatment Modalities.....	8
6. Moderate Dry Eye: Preferred Artificial Tears.....	9
7. Moderate Dry Eye: Preferred Steroids.....	10
8. Moderate Dry Eye: Sample Prescriptions.....	16
9. Adenoviral Conjunctivitis: Treatment Modalities.....	17
10. Adenoviral Conjunctivitis: Preferred Steroids.....	18
11. Adenoviral Conjunctivitis: Sample Prescriptions.....	23
12. Bacterial Conjunctivitis: Treatment Modalities.....	24
13. Bacterial Conjunctivitis: Preferred Category of Antibiotics.....	25
14. Bacterial Conjunctivitis: Preferred Antibiotics.....	25
15. Bacterial Conjunctivitis: Sample Prescriptions.....	28
16. Corneal Metallic Foreign Body: Treatment Modalities.....	29
17. Corneal Metallic Foreign Body: Antibiotic Solutions.....	30
18. Corneal Metallic Foreign Body: Antibiotic Ointments.....	30

19. Corneal Metallic Foreign Body: Cycloplegic Agents.....	31
20. Corneal Metallic Foreign Body: Bandage Contact Lens.....	31
21. Corneal Metallic Foreign Body: NSAIDs.....	32
22. Corneal Metallic Foreign Body: Sample Prescriptions.....	35
23. Bacterial Corneal Ulcer: Treatment Modalities.....	36
24. Bacterial Corneal Ulcer: Topical Antibiotic Agents.....	36
25. Bacterial Corneal Ulcer: Antibiotic Ointments.....	37
26. Bacterial Corneal Ulcer: Cycloplegic Agents.....	37
27. Bacterial Corneal Ulcer: Sample Prescriptions.....	40
28. Seasonal Allergic Conjunctivitis: Treatment Modalities.....	41
29. Seasonal Allergic Conjunctivitis: Topical Agents.....	42
30. Seasonal Allergic Conjunctivitis: Topical Steroids.....	42
31. Seasonal Allergic Conjunctivitis: Sample Prescriptions.....	46
32. Mild Anterior Uveitis: Treatment Modality.....	47
33. Mild Anterior Uveitis: Topical Steroid.....	47
34. Mild Anterior Uveitis: Cycloplegic Agents.....	48
35. Mild Anterior Uveitis: Sample Prescriptions.....	51
36. EBMD: Treatment Modalities.....	52
37. EBMD: Lubricating Agents.....	52
38. EBMD: Sample Prescriptions.....	55

## INTRODUCTION

The management of anterior segment ocular diseases requires the ability to not only appropriately diagnose conditions based on patient signs and symptoms, but also the ability to appropriately devise treatment plans. These treatment plans may require the use of pharmacological agents along with other therapeutic measures. The constant advancements and changes in the pharmaceutical industry can make it difficult for the novice clinician to determine the most appropriate medication to prescribe to a patient suffering from a specific diagnosis. Similarly, a student may feel confident that a category of treatment should be prescribed, but it may be difficult to translate textbook knowledge into clinical expertise. For instance, knowing that an antibiotic should be prescribed is not the same as knowing that a specific fourth generation fluoroquinolone should be prescribed and dosed at a specific time interval over a certain number of days.

A clinical instructional module was designed with the goal of enhancing current optometry students' comfort level with prescribing some commonly used therapeutic agents. Due to the multi-faceted thought process employed by practicing clinicians before writing a prescription, the survey was designed to eliminate some of these confounding factors. It is acknowledged that real clinical situations require treatment plans to be tailored to a patient's particular severity of symptoms, medical and/or ocular history, and insurance drug coverage among other issues; however, the aim of this research is to determine the most commonly preferred treatments at the present time for various anterior segment ocular conditions in this ever-evolving prescription drug industry.

The purpose of this research was to determine treatment modalities preferred by practicing optometrists in the state of Michigan for eight common anterior segment diagnoses and to use the data provided by the survey to devise a clinical instructional module for current optometry students. The eight diagnoses addressed in the survey were moderate dry eye, adenoviral conjunctivitis, bacterial conjunctivitis, 1 mm non-penetrating corneal metallic foreign body, 1 mm bacterial corneal ulcer, mild seasonal allergic conjunctivitis, mild anterior uveitis, and epithelial basement membrane dystrophy (EBMD, Cogan's Dystrophy, Map-Dot-Fingerprint Dystrophy). The diagnoses included in the survey were chosen based on anecdotal evidence of the frequency of encounters as well as the fact that these treatments often require pharmacologic treatment.



## METHODS

### *Survey Population*

An invitation to participate in a web-based survey (using kwiksurveys.com) was distributed via e-mail to approximately 750 members of the Michigan Optometric Association (MOA). Members of the MOA include current optometry students and non-practicing optometrists as well as currently licensed optometrists. MOA membership requires licensure as an optometrist in the state of Michigan; student memberships are available to optometry students. Participants were allowed a two-week window to respond to the survey, which consisted of multiple choice questions with the option of writing in alternate answers. All responses were anonymous.

### *Survey*

The survey consisted of a total of seventeen questions divided into two sections. The first section included four questions regarding demographic information of the respondents including age, sex, current practice modality, and years in practice. The second section asked participants to specify their preferred general treatment paradigm as well as specific therapeutic agents used in the treatment of anterior segment disorders commonly faced in primary care optometric practice. Diagnoses addressed in the survey included moderate dry eye, adenoviral conjunctivitis, bacterial conjunctivitis, corneal metallic foreign body, seasonal allergic conjunctivitis, mild anterior uveitis, and epithelial basement membrane dystrophy (EBMD, Cogan's dystrophy, map-dot-fingerprint dystrophy). The survey provided a number of treatment options, all of which were prudent treatments, and asked that the clinician choose which treatment option(s) they

would ideally (without limitations due to cost, availability, or patient allergy for example) choose to prescribe for each diagnosis. The questions were asked in both multiple choice and free-type format.

### *Statistical Analysis*

The survey results were analyzed in separate sections, coinciding with the development of instructional modules. As such, the results and discussion for each of the eight clinical modules are presented separately herein. A conservative margin of error was calculated for each of the eight modules. The conservative margin of error calculation provides an estimate of how well the data reflect the opinions of the entire population of eyecare providers treating a given disorder. In other words, if 18% of respondents report that they would prescribe a given agent and there is a 2% margin of error, then one can confidently estimate that 16-20% of the entire population of eyecare providers would also prescribe this agent.

### *Clinical Module Development*

Survey data and a comprehensive literature review were combined to devise a clinical instructional module for current optometry students in the form of a sample prescription pad. The sample prescription pad, although not a valid prescription, was developed as accurately as a prescription to be given to a patient suffering from a given diagnosis. Information provided includes medication name (generic and trade names), concentration, form of the medication, dosage, duration, bottle size, et cetera.

## RESULTS

The e-mail was sent to approximately 750 members of the Michigan Optometric Association; the MOA estimates an e-mail opening rate of 30-40%, suggesting that the survey invitation was received by approximately 225-300 members of the MOA. Over the two-week time period that the web-based survey was open to response, there were 89 respondents. Of the 89 respondents, 59.6% were male, and the distribution of ages among respondents was fairly equal (see Figures 1 and 2).

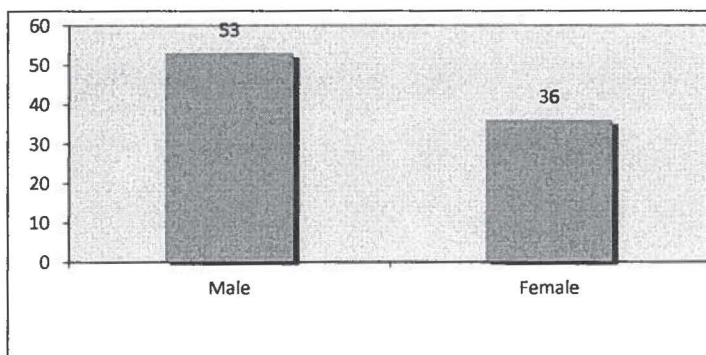


Figure 1.  
Demographics of  
Respondents: Number  
of Male versus Female  
Respondents

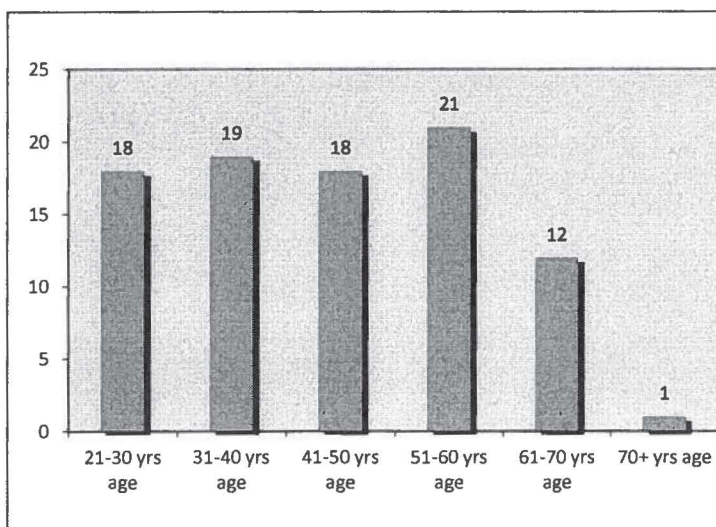


Figure 2. Demographics of  
Respondents: Number per  
Age Group

There was a unique distribution of reported years in practice among respondents, with the most respondents reporting years in practice as either 0-5 years (20 respondents) or over thirty years (19 respondents) (see Figure 3).

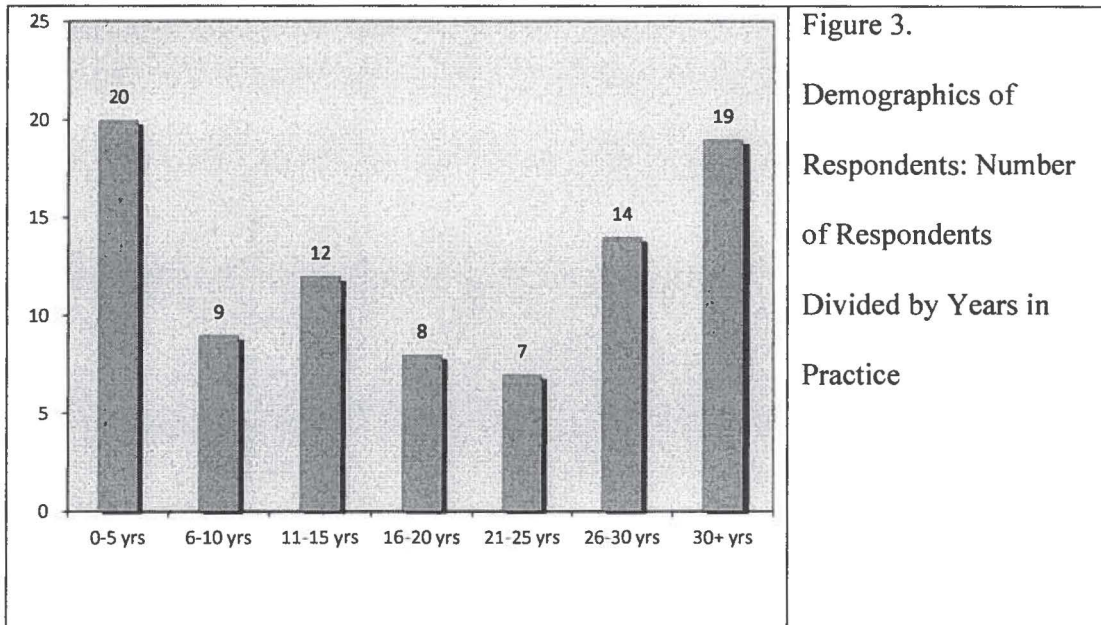


Figure 3. Demographics of Respondents: Number of Respondents Divided by Years in Practice

There was some disparity in distribution of respondents' mode of practice, with the majority reporting that they are currently employed in private practice (see Figure 4). Survey responses were not correlated to demographics of respondents.

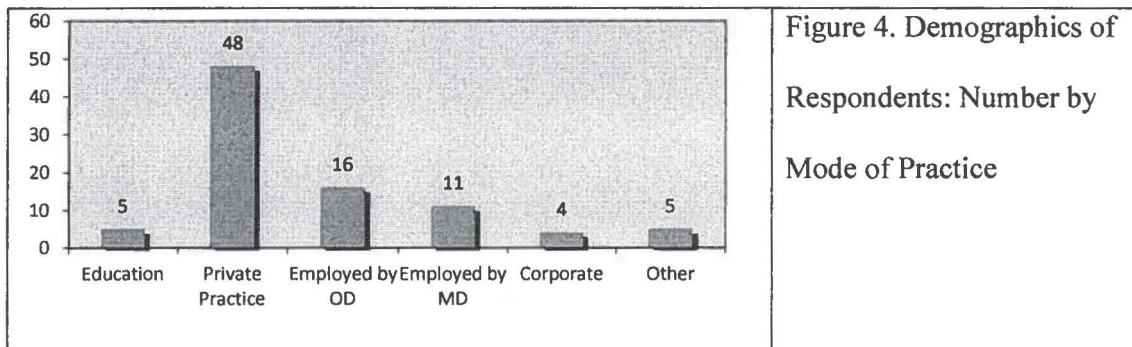


Figure 4. Demographics of Respondents: Number by Mode of Practice

The raw numbers and calculated percentages of demographics of participants may be found in Table 1.

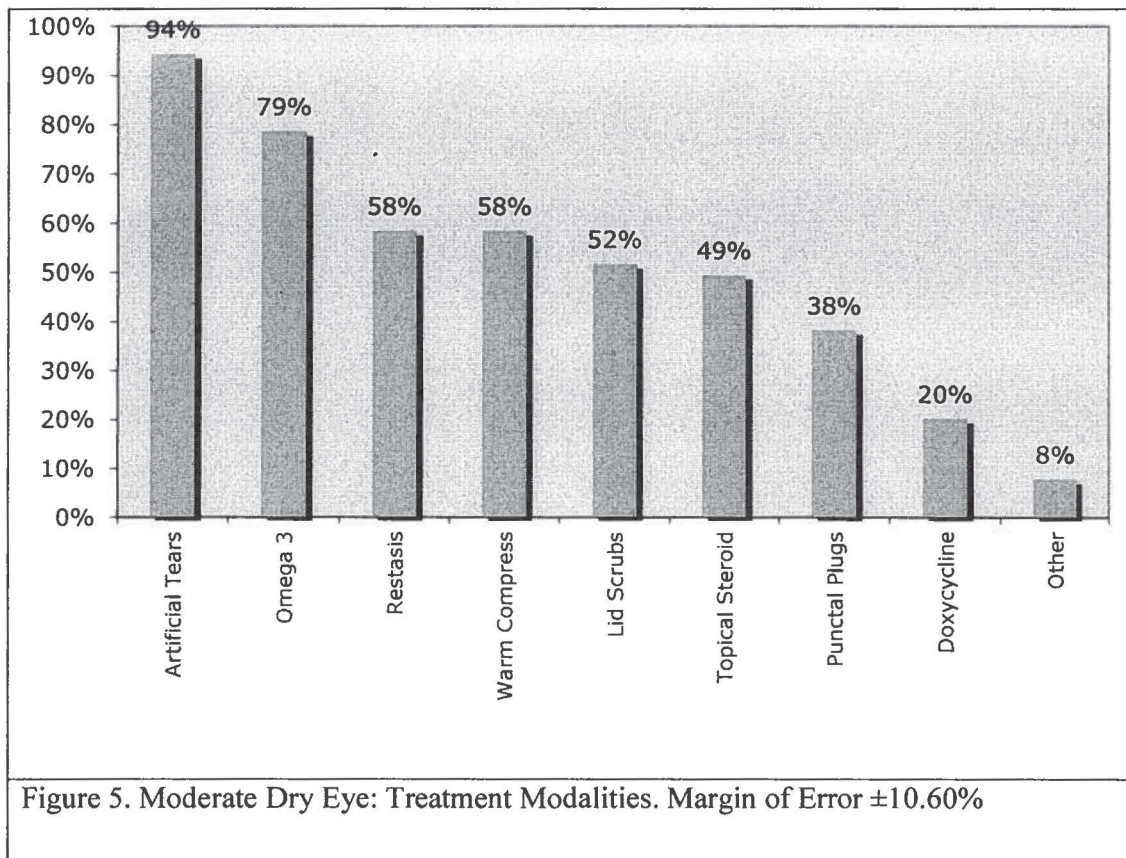
	Number	Percentage of Total
<b>Sex of Respondents</b>		
Male	53	59.55%
Female	36	40.45%
Total	89	
<b>Age Range of Respondents (years)</b>		
21-30	18	20.22%
31-40	19	21.35%
41-50	18	20.22%
51-60	21	23.60%
61-70	12	13.48%
70+	1	1.12%
Total	89	
<b>Years in Practice (years)</b>		
0-5	20	22.47%
6-10	9	10.11%
11-15	12	13.48%
16-20	8	8.99%
21-25	7	7.87%
26-30	14	15.73%
30+	19	21.35%
Total	89	
<b>Practice Modality</b>		
Educational Institution	5	5.62%
Private Practice	48	53.93%
Employed by OD	16	17.98%
Employed by MD	11	12.36%
Corporate	4	4.49%
Other	5	5.62%
Total	89	
<b>Table 1. Demographics of Respondents</b>		



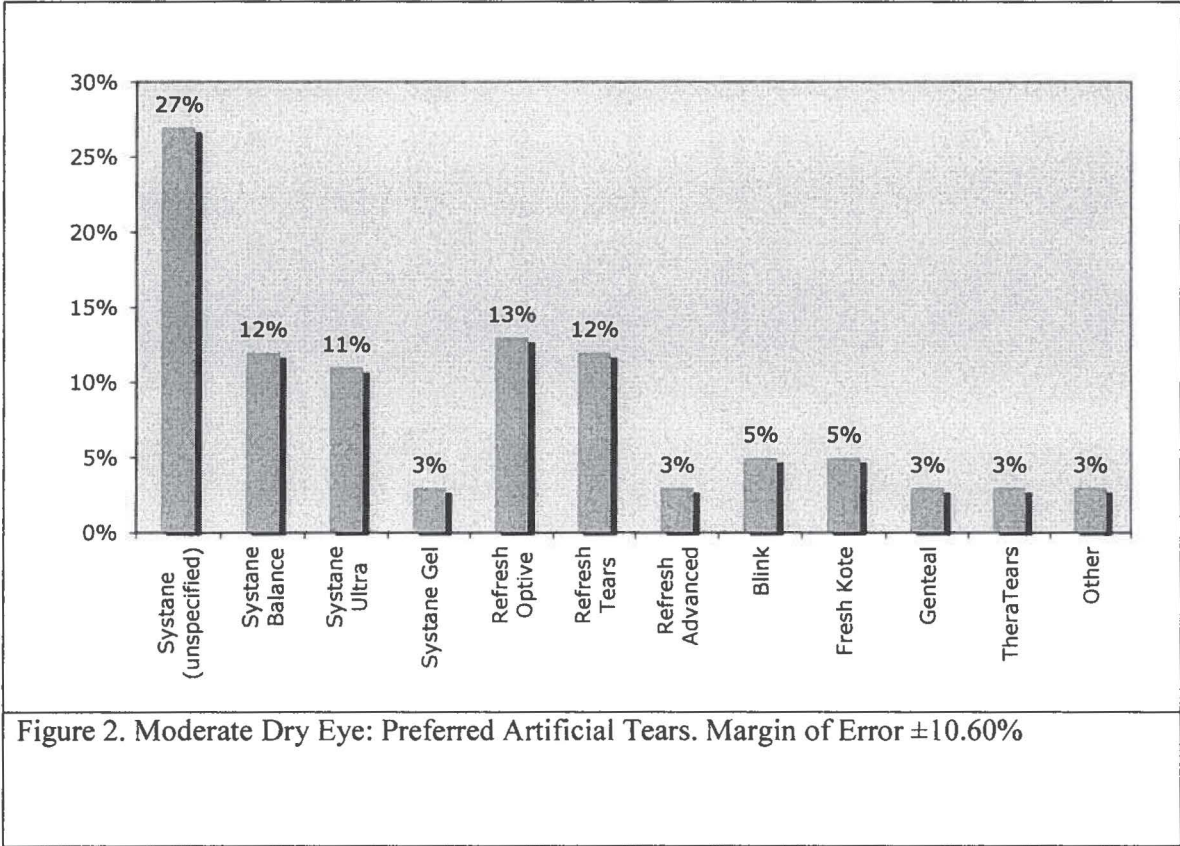
## 1. Instructional Module 1: Moderate Dry Eye

### Results

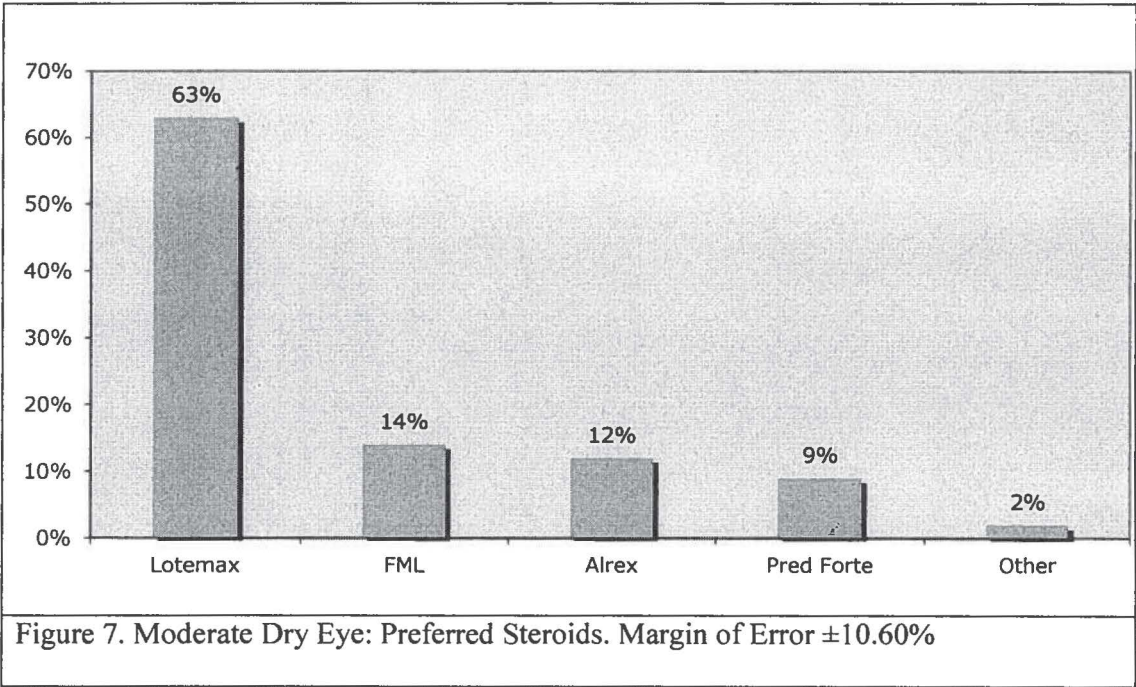
There were 89 respondents to the moderate dry eye questions, resulting in a conservative margin of error of 10.60%, providing a rough reflection of the confidence interval around each data point as discussed in the Methods section. The majority of respondents (94%) reported that they would prescribe artificial tears in the case of a patient with moderate dry eye symptoms. Other common treatment modalities included omega 3 fatty acid supplements (79%), cyclosporine ophthalmic suspension (Restasis, Allergan, California) (58%), warm compresses (58%), lid scrubs (52%), topical steroid (49%), punctal plugs (38%), doxycycline (20%), and other (8%). (See Figure 5).



When asked if there was a specific variety of artificial tear prescribed, there were 153 responses. There were a variety of preferred artificial tears selected by respondents, but the majority report prescribing an unspecified Systane® brand drop (Alcon Laboratories, USA) (27%) (See Figure 6).



Nearly half of respondents reported that they would prescribe a steroid for moderate dry eye. When asked to specify a steroid, there were 57 responses with the majority (63%) of those responding that they would prescribe 0.5% loteprednol etabonate (Lotemax, Bausch & Lomb, USA). Other common steroids chosen include fluorometholone (FML) (14%), 0.2% loteprednol etabonate (Alrex, Bausch & Lomb, USA) (12%), prednisolone acetate (PredForte, Allergan, USA) (9%), and other (2%). (See Figure 7)



There were only two respondents in regards to brands of Omega-3 fatty acids prescribed; both respondents specified MaxiTears (MedOp, Inc., Florida).



## *Discussion*

### *1.1 Artificial Tears*

Artificial tears have long been the mainstay of treatment for dry eye. Of the optometrists surveyed, 94% recommended the use of artificial tears to their dry eye patients. Dry eye causes a loss of aqueous and a subsequent hypertonic ocular environment and artificial tears function to replace this aqueous level of the tear film.<sup>1</sup> Dry eye is also often associated with blurred vision due to increased light scattering and research has proven artificial tears to significantly decrease light scattering and subsequent blurred vision for up to one hour after installation along with enhancing ocular comfort.<sup>2</sup>

Although most surveyed optometrists use artificial tears in dry eye management, there was a great variety in the preferred brand of artificial tear, as each brand has differences in active ingredients, viscosity, and use of preservatives. The two most commonly recommended brands in the surveyed optometrists were Systane and Refresh (Allergan, USA), which have active ingredients of polyethelene glycol and carboxymethylcellulose respectively, with various preservatives depending on the particular type of each brand used.

### *1.2 Omega-3 Fatty Acids*

Omega-3 fatty acid supplements, or fish oil, are another commonly used medication in the treatment of dry eye, as 84% of surveyed optometrists employ a fish oil regimen. Fish oil improves dry eye by decreasing inflammation, decreasing cell apoptosis, stimulating tear secretion, and thinning oil produced by the meibomian glands especially in cases of meibomian gland dysfunction and/or blepharitis.<sup>1</sup> Since omega-3s are essential fatty

acids, they must be obtained via diet or supplements and cannot be manufactured by the body.<sup>1</sup> The positive effects of omega-3s were proven in a 2005 Harvard Medical School study that found a 34% lower prevalence of dry eye in women that had the highest omega-3 to omega-6 ratio in their diet.<sup>3</sup> The ideal ratio of omega-3s to omega-6s is 1:2.3; however, unfortunately, most Americans have a ratio of 1:10.<sup>1</sup>

There are various brands of fish oil supplements, but a commonly recommended dosage for dry eye is 2,000mg daily.<sup>4</sup> Independent of chosen brand, the effects of fish oil can take up to four to six months, so it is important to educate patients that the benefits of the medication may not be immediate.<sup>4</sup> It is also important to communicate with a patient's primary care physician before starting a fish oil regimen, as such a regimen can be contraindicated in patients on blood thinners or with high cholesterol due to its potential to increase bleeding and levels of low-density lipoproteins.<sup>5</sup>

### *1.3 Restasis*

Restasis, or cyclosporine, was employed by over 50% of surveyed optometrists for dry eye treatment. It is the only current prescription medication approved by the FDA for the treatment of chronic dry eye.<sup>6</sup> However, as Restasis is an immunosuppressive agent, it is only effective in dry eye cases with an inflammatory component such as in concurrent meibomian gland dysfunction. Also, due to such anti-inflammatory effects, it follows that it should be used with caution in patients with active ocular infections. Restasis comes in single-use vials and is dosed twice a day. Like fish oil supplements, the positive effects can take a few months for patients to notice and patient education regarding such is imperative.

#### *1.4 Warm Compresses/Lid scrubs*

The judicious use of warm compresses and lid scrubs is another commonly used treatment option in dry eye patients, as over 50% of surveyed optometrists recommend such a regimen. These treatment modalities are used when there is a concurrent meibomian gland dysfunction or blepharitis component to the dry eye, as the warm compresses serve to open the meibomian gland orifices and lid scrubs cleanse the lid margins. For lid scrubs, many optometrists simply recommend baby shampoo; however, current trends show an increase in the use of commercial lid scrub products, which tend to increase patient compliance when prescribed to patients.<sup>4</sup>

#### *1.5 Topical Steroids*

Topical steroids are another anti-inflammatory agent used and approved by the FDA for the treatment of dry eye and just fewer than 50% of surveyed optometrists use this treatment option.<sup>6</sup> Various research endeavors support this approach and have shown the use of steroids in dry eye patients to decrease ocular irritation, superficial punctate keratitis, and self-reported symptoms.<sup>7</sup> Furthermore, the effects of steroids are quick; therefore, they can be used as a stand-alone treatment to rapidly decrease symptoms or they can be used concurrently while waiting for the effects of other agents, such as Restasis. However, due to their risk of increasing IOP, causing posterior subcapsular cataracts, and increasing the risk for ocular infections, steroids are typically only used on a short-term basis.<sup>7</sup> Safety profile is important when determining which class of steroids to use for dry eye management. Studies have shown loteprednol etabonate 0.5% (Lotemax) to be associated with a 2% chance of increased IOP after 4 weeks of use

versus a 7% chance of increased IOP with prednisolone acetate 1% (PredForte).<sup>7</sup> This was reflected in our survey data, as the most commonly prescribed steroid by far was Lotemax.

### *1.6 Punctal Plugs*

Punctal plugs are a form of dry eye treatment that are typically saved for recalcitrant cases that do not respond to first-line therapy measures. Thirty-eight percent of surveyed optometrists reported that they would employ punctal plugs in dry eye treatment.

Punctal plugs work to increase the tear meniscus by preventing the drainage of tears through the puncta. The tear meniscus plays a vital role in ocular lubrication, as it contains approximately 75-90% of the total tear volume.<sup>8</sup> In addition to increasing tear menisci volumes, studies conducted on contact lens patients found punctal plug insertion to also increase tear break-up time and overall patient-reported ocular comfort.<sup>8</sup>

Currently, research is being conducted on the use of punctal plugs as vectors to deliver cyclosporine A to further enhance dry eye treatment.<sup>9</sup>

### *1.7 Doxycycline*

Oral doxycycline was the least commonly used treatment modality among surveyed optometrists. Doxycycline inhibits matrix metalloproteinase 9, which is found in increased concentrations in dry eye patients, and thus prevents disruption to the corneal epithelium.<sup>1</sup> Research has shown low dose doxycycline to be effective in increasing tear break-up time, increasing tear volume, and decreasing patient symptoms.<sup>10</sup> Doxycycline is most beneficial in case of dry eye/blepharitis with chronic meibomianitis. However, it should not be used in pregnant women or children under 8 and should be used with

caution in asthmatics, patients with liver disease, patients with kidney disease, women on birth control, and patients with high exposure to sunlight.<sup>11</sup>

*Instructional Module*

Based on the findings of the survey and literature review, sample prescriptions for specific cyclosporine, mild steroid, omega-3 fatty acid, tetracycline, and artificial tear agents were developed. The sample prescriptions may be found on the following page in Figure 8.

The figure displays five sample prescription forms from the University Eye Center, 1124 S. State Street, Big Rapids, MI 49307. Each form is structured as follows:

- Header:** University Eye Center, 1124 S. State Street, Big Rapids, MI 49307
- Patient Information:** Name, Address, DOB, Date
- Prescription:** R [Drug Name] [Quantity] [Frequency]
- Label Section:**  Label, Refill [Number] times, O.D. [Frequency], Dispense as written

The five prescriptions are:

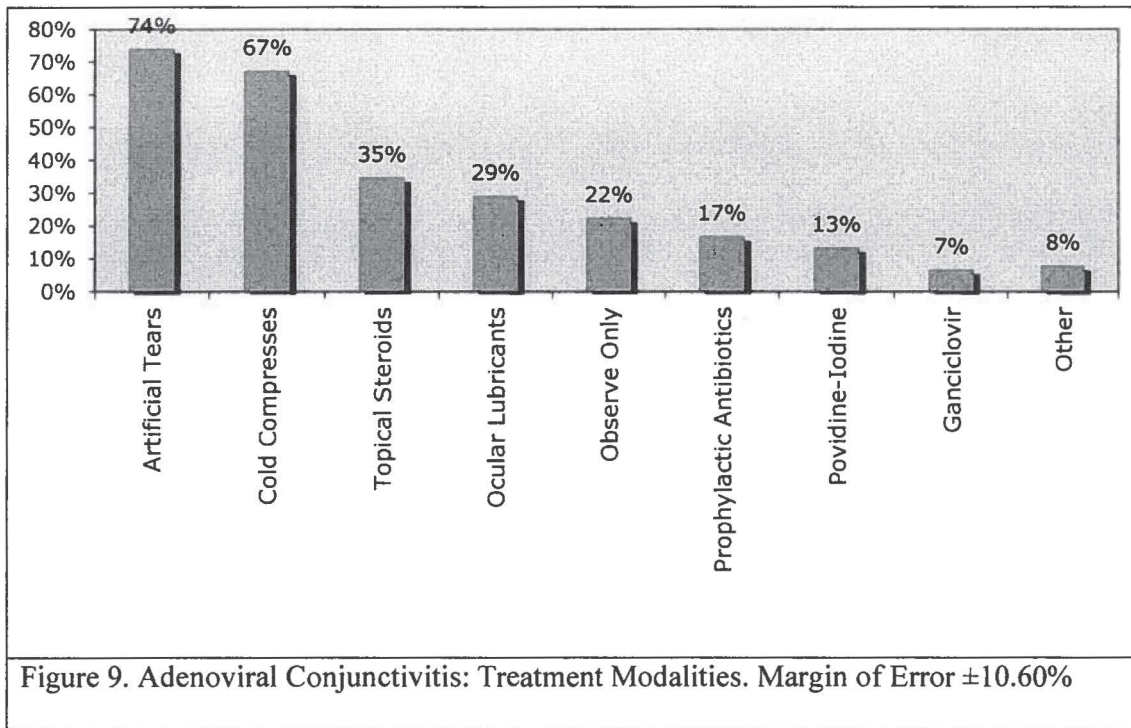
- Prescription 1:** Restasis (5 boxes - 90 day supply) 1 drop bid OU
- Prescription 2:** Lotemax solution 5 mL bottle 1 drop bid OU x 1 month
- Prescription 3:** MasTears Dry Eye (1 bottle - 120 capsules) 4 tablets by mouth per day (take with food)
- Prescription 4:** Doxycycline 100 mg tablets (1 bottle - 60 tablets) 1 tablet po qd x 4 month (maintain a dose of 20-40mg qd if needed thereafter)
- Prescription 5:** Systane Ultra 10 mL bottle 1 drop tid-qid OU

Figure 8. Moderate Dry Eye: Sample Prescriptions

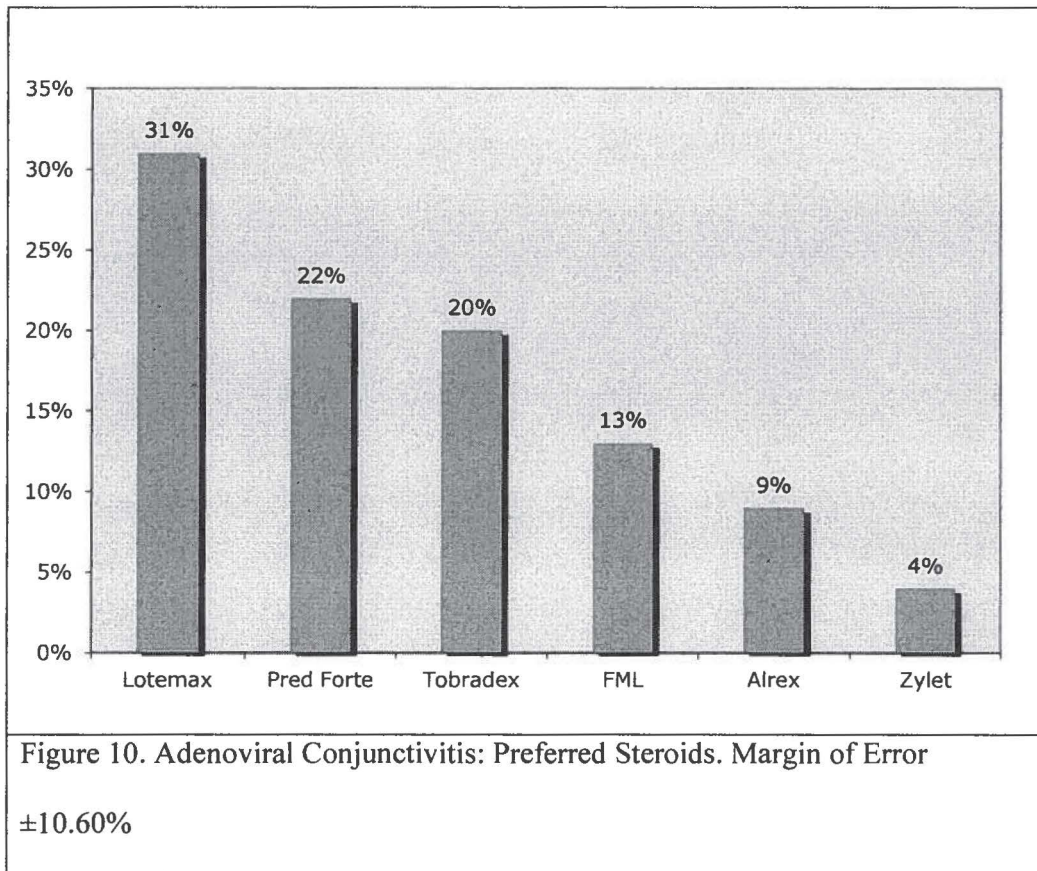
## 2. Instructional Module 2: Adenoviral Conjunctivitis

### Results

There were 89 respondents to the adenoviral conjunctivitis questions, resulting in a conservative margin of error of 10.60% providing a rough reflection of the confidence interval around each data point as discussed in the Methods section. For patients with adenoviral conjunctivitis, the majority of respondents stated that they would prescribe artificial tears (74%) and/or cold compresses (67%). Other common agents prescribed include topical steroids (35%), ocular lubricants (29%), prophylactic antibiotics (17%), povidone-iodine (13%), ganciclovir (7%), or other (8%). Roughly one-fifth of respondents stated that they would choose to monitor the condition without treatment (observe only: 22%). (See Figure 9)



Among the 31 respondents stating that they would prescribe steroids, there were 45 steroids selected. Roughly one-third stated that they would prescribe Lotemax (31%). Other common choices included PredForte (22%), tobramycin/dexamethasone (Tobradex, Alcon, USA) (20%), fluorometholone (13%), Alrex (9%), and 0.5% loteprednol etabonate/tobramycin (Zylet, Bausch & Lomb, USA) (4%). (See Figure 10).



### *Discussion*

Although adenoviral infections can range from minor to quite severe (as is seen in epidemic keratoconjunctivitis), it is considered a benign and self-limiting disease with no generally accepted treatment regimen.<sup>12</sup> In fact, 22% of respondents to this survey stated



that they would only observe a patient diagnosed with adenoviral conjunctivitis. The course of a typical adenoviral infections ranges from 14-21 days.<sup>13</sup> Researchers emphasize that adenoviral conjunctivitis infections are considered a threat to the public's health due to their communicability and virulence, so efforts should be made by the practitioner to minimize transmission.<sup>12</sup> Practitioners typically focus on treatment that will provide some patient relief, may shorten the course of the disease, and/or prevent progression to a bacterial infection.

### *2.1 Symptomatic Relief*

The majority of practitioners reported prescribing agents and treatment modalities intended to increase patient comfort, with 74% prescribing artificial tears, 67% prescribing cold compresses, and 29% prescribing ocular lubricants. A review of the literature indicates that symptomatic relief, proper hygiene and patient isolation to reduce the spread of infection are the most important and clinically effective avenues available at this time.<sup>14</sup>

### *2.2 Topical Steroids*

A careful review of the literature confirms that the prescription of steroids for viral conjunctivitis is controversial. However, all literature emphasizes the importance of accurate diagnosis, ruling out herpetic, *Acanthamoeba*, or other infection before steroids are used. The extended course and discomfort associated with adenoviral conjunctivitis motivates many practitioners to prescribe topical steroids, hoping to ameliorate some of the patient's signs and symptoms which may include watering, itching, burning, pain, photophobia, swelling of the lids, conjunctival hyperemia, chemosis, or decreased vision

related to punctate keratitis or corneal infiltrates.<sup>15-16</sup> In this survey, 35% of practitioners reported that they would prescribe topical corticosteroids or steroid/antibiotic combination for adenoviral conjunctivitis. Of these respondents, the majority reported that they would prescribe a mild steroid including Lotemax (31%), FML (20%), or Alrex (9%). Twenty-two percent reported that they would prescribe PredForte. Nearly one-quarter of these respondents reported that they would prescribe a steroid/antibiotic combination drop such as TobraDex (20%) or Zylet (4%).

Whether or not a practitioner prescribes a steroid in the case of viral conjunctivitis is highly personal, and it is essential to remember that steroids simultaneously increase patient comfort and the duration of the disease. Clinical research does not provide any more insight to this dilemma, often providing neutral or contradictory conclusions. For instance, in a randomized clinical trial of patients with confirmed viral follicular conjunctivitis comparing the topical corticosteroid dexamethasone with hypromellose vehicle lubricating drop, patients being treated with the steroid were more likely to report that the drop improved their symptoms, but there were no significant differences in redness or patients' rating of their own discomfort.<sup>13</sup> Regardless of a clinician's preference regarding use of steroids, it is of utmost importance that the clinician has accurately diagnosed the patient before steroids are prescribed.

### *2.3 Ganciclovir*

Shortly after the FDA approval of topical ganciclovir gel for Herpetic infections, there was some interest in the use of this antiviral for the treatment of adenoviral conjunctivitis. In this survey, 7% of respondents reported that they would prescribe ganciclovir.

Unfortunately, topical antiviral agents have historically been developed with Herpes virus infections in mind, and have not been found to significantly decrease the duration or severity of the course of adenoviral infections.<sup>12</sup> Clinical research is on-going; *in vitro* studies show that ganciclovir may inhibit some strains of adenovirus but its clinical value has not yet been established.<sup>14</sup>

#### *2.4 Povidone-Iodine*

Thirteen percent of respondents reported that they would perform a povidone-iodine wash on patients with adenoviral conjunctivitis. This is a non-specific disinfectant that can kill extracellular virus but not intracellular virus particles.<sup>14</sup> This treatment modality is somewhat controversial because it can only reach extracellular virus particles and because patient discomfort is increased during the treatment even when topical anesthetic is used. There is some interest in a new treatment combining the steroid dexamethasone with povidone iodine, providing symptomatic relief in the form of steroids and reducing spread of infection by killing virus particles found in tears.<sup>14</sup>

#### *2.5 Prophylactic Antibiotics*

Seventeen percent of respondents reported that they would prescribe prophylactic antibiotics, with most specifying that they would prescribe fourth generation fluoroquinolones. For many years, clinicians have prescribed an antibiotic to prevent a concomitant bacterial conjunctivitis, but some clinicians state that such an approach creates an undue expense to the patient with no established clinical value.<sup>14</sup> Kaufman reports that even if concomitant bacterial infection arises, which is rare, a bacterial infection would resolve on its own during the course of a viral infection.<sup>14</sup> A case report

in which topical ciprofloxacin was prescribed for adenoviral conjunctivitis warns that there is potential for some harm to the patient; topical ciprofloxacin has side effects including formation of crystalline corneal epithelial precipitates which can create an irregular corneal surface and associated pain, reduced vision, and delayed recovery.<sup>17</sup>

## *2.6 Other*

Some of the miscellaneous responses provided by practitioners included topical antihistamines such as ketotifen fumarate (Zaditor, Novartis, USA) and topical decongestants both available over the counter. Indeed, these treatments are known to help with symptoms and conjunctival injection without risk of prolonging infection.<sup>16</sup> Some authors suggest prescribing a non-steroidal anti-inflammatory in lieu of a steroid, with some reports of increased patient comfort, although it should be noted that NSAIDs are ineffective in controlling replication of adenovirus.<sup>12,16</sup>

New technology is making definitive diagnosis of adenoviral infections possible same-day in primary care optometric practice, with the increasing availability of the AdenoPlus Test (RPS Pathogen Screening, Inc., USA). Research indicates that the AdenoPlus Test is more cost-effective than traditional cytological studies and has been found to be 100% sensitive and 100% specific in the detection of adenoviral infections.<sup>18</sup> Medicare reimbursement for performing the test was reported as \$17 in 2012, using the HCPCS billing code 87809QW (infectious agent antigen detection by immunoassay with direct optical observation; Adenovirus) according to the makers of the AdenoPlus Test.<sup>19</sup>

*Instructional Module*

Based on the findings of the survey and literature review, sample prescriptions for specific mild steroid, antibiotic, and artificial tear agents were developed. Literature review did not include a generally accepted regimen for topical antivirals; thus antivirals are excluded from the module. The sample prescriptions may be found below in Figure 11.

University Eye Center  
1124 S. State Street  
Big Rapids, MI 49307

Name: \_\_\_\_\_ DOB: \_\_\_\_\_  
Address: \_\_\_\_\_ Date: \_\_\_\_\_

**R** Lotemax z soles 1 ml. bottle  
1 drop bid OU x 1 week

Label  
Refill:   0   times

\_\_\_\_\_ Q.D. \_\_\_\_\_ Q.D.  
\*Label Responder Permitted Number of refills

University Eye Center  
1124 S. State Street  
Big Rapids, MI 49307

Name: \_\_\_\_\_ DOB: \_\_\_\_\_  
Address: \_\_\_\_\_ Date: \_\_\_\_\_

**R** Polybin ophthalmic soles - 10 mL bottle  
1 drop qid OU x 7 days

Label  
Refill:   0   times

\_\_\_\_\_ Q.D. \_\_\_\_\_ Q.D.  
\*Label Responder Permitted Number of refills

University Eye Center  
1124 S. State Street  
Big Rapids, MI 49307

Name: \_\_\_\_\_ DOB: \_\_\_\_\_  
Address: \_\_\_\_\_ Date: \_\_\_\_\_

**R** Systane Ultra 10 ml. bottle  
1 drop bid-qid OU

Label  
Refill:   04   times

\_\_\_\_\_ Q.D. \_\_\_\_\_ Q.D.  
\*Label Responder Permitted Number of refills

University Eye Center  
1124 S. State Street  
Big Rapids, MI 49307

Name: \_\_\_\_\_ DOB: \_\_\_\_\_  
Address: \_\_\_\_\_ Date: \_\_\_\_\_

**R** Refresh Cellulose 1 box (30 vials)  
1 drop bid OU x 1 week

Label  
Refill:   0   times

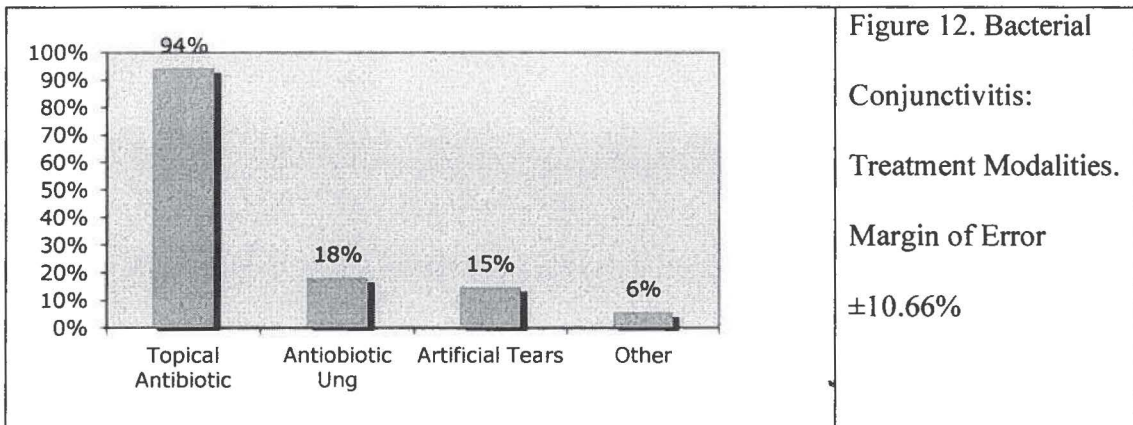
\_\_\_\_\_ Q.D. \_\_\_\_\_ Q.D.  
\*Label Responder Permitted Number of refills

Figure 11. Adenoviral Conjunctivitis: Sample Prescriptions

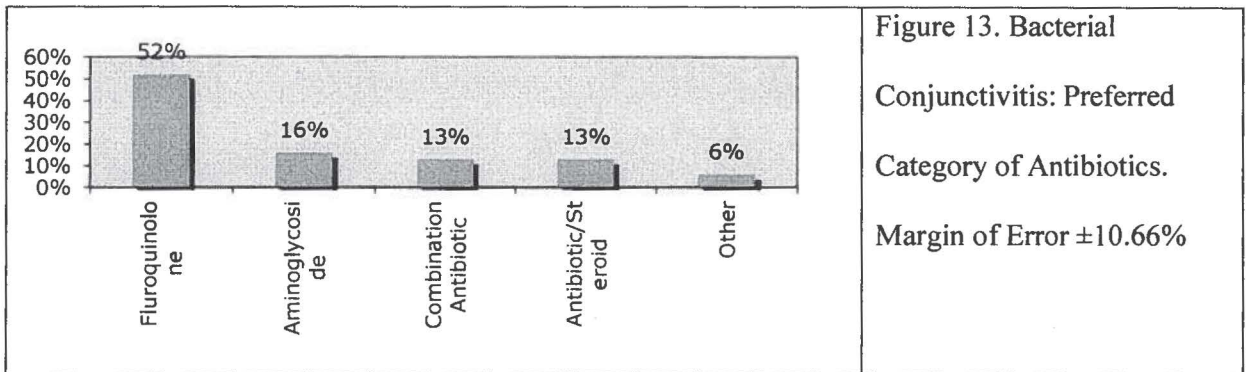
### 3. Instructional Module 3: Bacterial Keratoconjunctivitis

#### Results

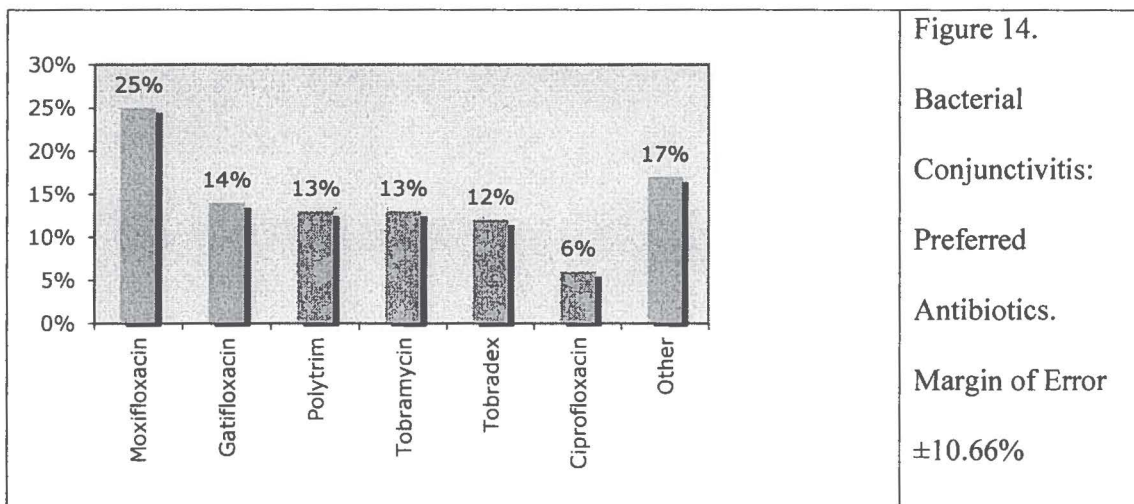
There were 88 respondents to the adenoviral conjunctivitis questions, resulting in a conservative margin of error of 10.66% providing a rough reflection of the confidence interval around each data point as discussed in the Methods section. For patients with an unspecified bacterial keratoconjunctivitis, the majority of respondents stated that they would prescribe a topical antibiotic solution (94%). Other common responses included antibiotic ointment (18%), artificial tears (15%), or other (6%). (Figure 12)



There were 163 responses when respondents were asked to specify the antibiotic agent(s) that they would prescribe for bacterial keratoconjunctivitis. By category, the most common agents prescribed were fluoroquinolones (52%), followed by aminoglycosides (16%), combination antibiotics (13%), antibiotic/steroid combination drugs (13%), or other (6%). (Figure 13)



Specific antibiotics reportedly prescribed by respondents include moxifloxacin (25%), gatifloxacin (14%), polytrim (13%), tobramycin (13%), tobradex (12%), ciprofloxacin (6%), or other (17%). (Figure 14)



## *Discussion*

Bacterial conjunctivitis is a self-limiting disease, but antibiotic agents are typically recommended to shorten the disease process.<sup>20</sup> This was reflected in the 94% of surveyed optometrists that reported managing this condition with topical antibiotic medications. The benefits of antibiotics, however, are most notable if the condition is caught early, as they have limited clinical effects if started several days after the onset of the infection.<sup>20</sup>

### *3.1 Topical Antibiotics*

Although most surveyed optometrists agreed with the use of topical antibiotics to treat bacterial infections, there was a wide variety in the antibiotic of choice. The most common antibiotics used by surveyed optometrists were as follows: 39% fourth-generation fluoroquinolones (moxifloxacin and gatafloxacin), 13% polytrim, 13% tobramycin, 12% tobradex, 6% ciprofloxacin, and 17% other agents.

Culturing is by far the most accurate means to determine the appropriate antibiotic. However, due to the self-limiting nature of most bacterial infections and the costs associated with such testing, a broad-spectrum antibiotic is typically instituted at the onset of the infection with culturing reserved for recalcitrant cases. Agents with good broad-spectrum coverage include ciprofloxacin, ofloxacin, quixin, polytrim, gentamicin, tobramycin, moxifloxacin, and gatifloxacin.<sup>20</sup>

An important issue when choosing the appropriate antibiotic to prescribe is the increasing prevalence of antibiotic resistance.<sup>20-21</sup> According to the Antibiotic Resistance Monitoring in Ocular Microorganisms (ARMOR) study 39% of ocular isolates of *S. aureus* were methicillin resistant and 38% were fluoroquinolone resistant. While 53% of



ocular *Staphylococci* organisms were methicillin resistant and 43% were fluoroquinolone resistant.<sup>21</sup> The biggest culprits responsible for this increase in ocular antibiotic resistance are oral antibiotics and antibiotics put into livestock feed that humans end up ingesting.<sup>20-</sup>  
<sup>21</sup> However, topical agents are contributing to the issue as well through both over-prescription and dosing below therapeutic levels.<sup>20-21</sup> Therefore, it is recommended that the most potent antibiotics, such as fourth-generation fluoroquinolones, be reserved for sight-threatening conditions and for all antibiotics to be dosed at appropriate levels.<sup>21</sup>

Although fourth-generation fluoroquinolones are considered top-of-the-line treatment for bacterial infections, only 15-30% of methicillin-resistant *Staphylococcus aureus* (MRSA) infections are responsive to these agents according to the Ocular Tracking Resistance in the United States Today (TRUST) study.<sup>21</sup> Treatment with polytrim, sulfacetamide, or fortified vancomycin is recommended for these patients.<sup>21</sup> Also of importance, is that besifloxacin is purely an ophthalmic antibiotic and does not exist in oral formulation; therefore, it may potentially be less susceptible to future resistance issues.<sup>21</sup>

### 3.2 Other

Although antibiotics are the mainstay of treatment in bacterial infections, antibiotic medications only destroy the bacterial agents and do not inhibit the associated inflammation. Therefore, if there is no corneal compromise a concurrent steroid or an antibiotic/steroid combination drop is recommended to further quicken recovery.<sup>20</sup>

Artificial tears may help with patient comfort, and 15% of respondents reported that they would prescribe artificial tears.

*Instructional Module*

Based on the findings of the survey and literature review, sample prescriptions for three antibiotics, an antibiotic/steroid, and artificial tear agents were developed. The sample prescriptions may be found below in Figure 15.

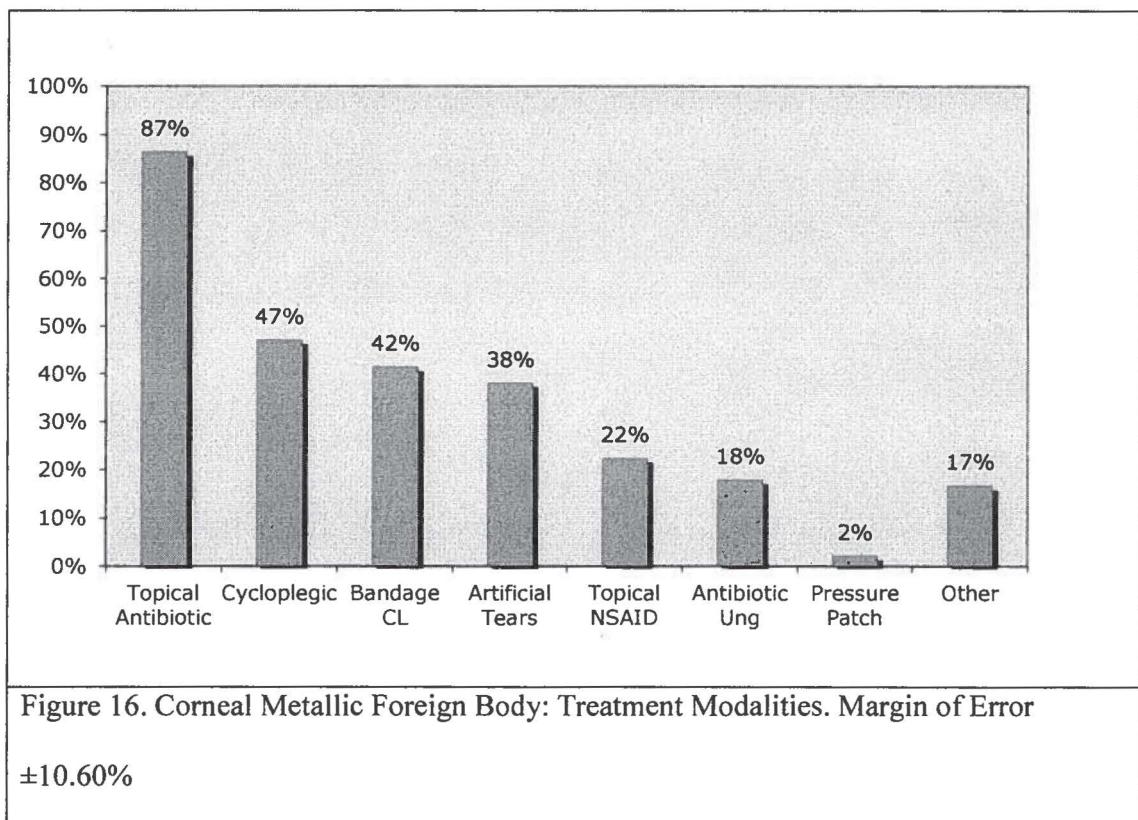
<p style="text-align: center;">University Eye Center 1124 S State Street Big Rapids, MI 49307</p> <hr/> <p>Name: _____ DOB: _____ Address: _____ Date: _____</p> <p><b>R</b> Moxeza (moxifloxacin) ophthalmic soln 1 mL 1 gtt bid OU x 7 days</p> <p><input type="checkbox"/> Label: Refill: <u>  0  </u> times _____ O.D. _____ O.D. <small>Pharmaceutical Formulation      Dispense as written</small></p>	<p style="text-align: center;">University Eye Center 1124 S State Street Big Rapids, MI 49307</p> <hr/> <p>Name: _____ DOB: _____ Address: _____ Date: _____</p> <p><b>R</b> Polytrim ophthalmic soln - 10 mL bottle 1 drop qid OU x 3 days</p> <p><input type="checkbox"/> Label: Refill: <u>  0  </u> times _____ O.D. _____ O.D. <small>Pharmaceutical Formulation      Dispense as written</small></p>
<p style="text-align: center;">University Eye Center 1124 S State Street Big Rapids, MI 49307</p> <hr/> <p>Name: _____ DOB: _____ Address: _____ Date: _____</p> <p><b>R</b> Tobrex ophthalmic suspension - 5 mL bottle 1 gtt qid OU x 7-10 days</p> <p><input type="checkbox"/> Label: Refill: <u>  0  </u> times _____ O.D. _____ O.D. <small>Pharmaceutical Formulation      Dispense as written</small></p>	<p style="text-align: center;">University Eye Center 1124 S State Street Big Rapids, MI 49307</p> <hr/> <p>Name: _____ DOB: _____ Address: _____ Date: _____</p> <p><b>R</b> Tobrex (tobramycin) 0.3% ophthalmic ung Apply 1/2 inch ribbon to lower lids qd-bid</p> <p><input type="checkbox"/> Label: Refill: <u>  0  </u> times _____ O.D. _____ O.D. <small>Pharmaceutical Formulation      Dispense as written</small></p>
<p style="text-align: center;">University Eye Center 1124 S State Street Big Rapids, MI 49307</p> <hr/> <p>Name: _____ DOB: _____ Address: _____ Date: _____</p> <p><b>R</b> Tobrex (tobramycin) 0.3% ophthalmic soln 1 gtt qid OU x 7-10 days</p> <p><input type="checkbox"/> Label: Refill: <u>  0  </u> times _____ O.D. _____ O.D. <small>Pharmaceutical Formulation      Dispense as written</small></p>	<p style="text-align: center;">University Eye Center 1124 S State Street Big Rapids, MI 49307</p> <hr/> <p>Name: _____ DOB: _____ Address: _____ Date: _____</p> <p><b>R</b> Systane Ultra 10 mL bottle 1 drop tid-qid OU</p> <p><input type="checkbox"/> Label: Refill: <u>  0  </u> times _____ O.D. _____ O.D. <small>Pharmaceutical Formulation      Dispense as written</small></p>

Figure 15. Bacterial Conjunctivitis: Sample Prescriptions

#### 4. Instructional Module 4: Corneal Metallic Foreign Body

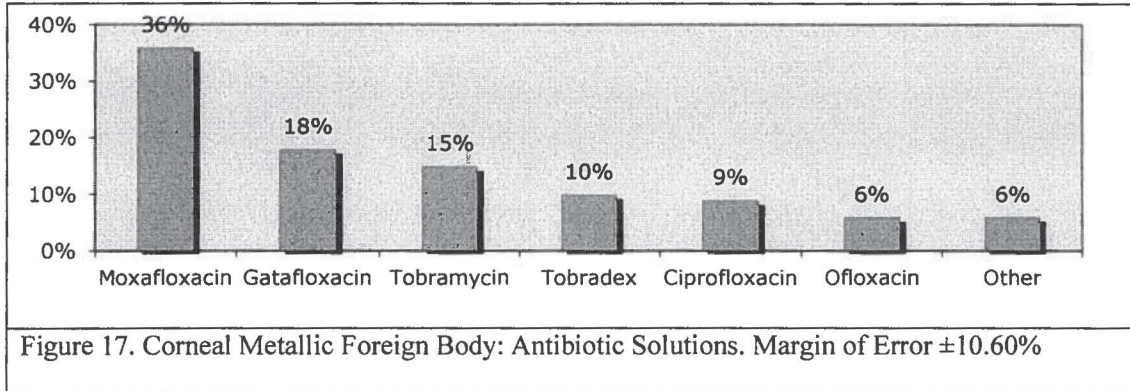
There were 89 respondents to the corneal metallic foreign body questions, resulting in a conservative margin of error of 10.60% providing a rough reflection of the confidence interval around each data point as discussed in the Methods section. For patients with a corneal metallic foreign body removed in-office, agents prescribed included topical antibiotic (87%), cycloplegic (47%), bandage contact lens (42%), artificial tears (38%), topical NSAID (22%), antibiotic ointment (18%), pressure patch (2%), and other (17%).

(Figure 16)

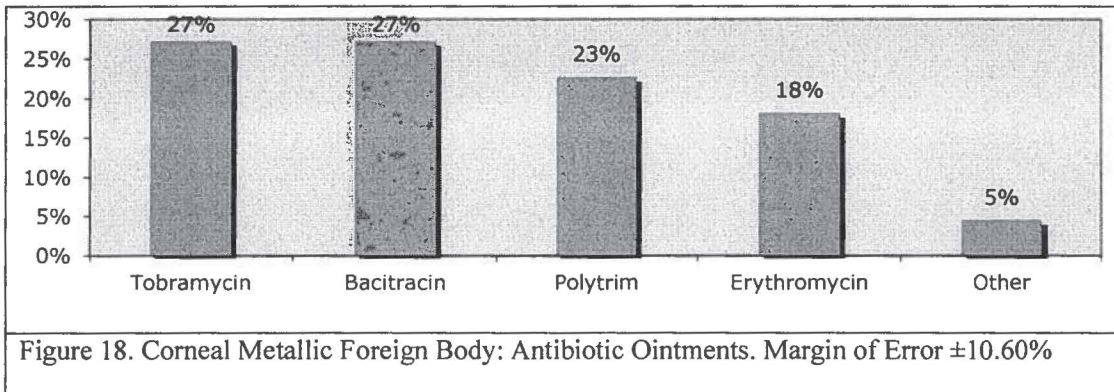


Respondents reported using both antibiotic solutions and antibiotic ointments. There were eighty antibiotic solutions reported include moxifloxacin (36%), gatafloxacin (18%), tobramycin (15%), tobradex (10%), ciprofloxacin (9%), ofloxacin (6%), or other (6%).

(Figure 17)



The 22 antibiotic ointments selected by respondents included tobramycin (27%), bacitracin (27%), polytrim (23%), erythromycin (18%), and other (5%). (Figure 18)



Among the forty-two respondents that reported prescribing a cycloplegic agent, there were 33 cycloplegic agents specified. The cycloplegic agents specified include



homatropine (55%), cyclopentolate (30%), atropine (6%), scopolamine (6%), and mydriacyl (2%). (Figure 19)

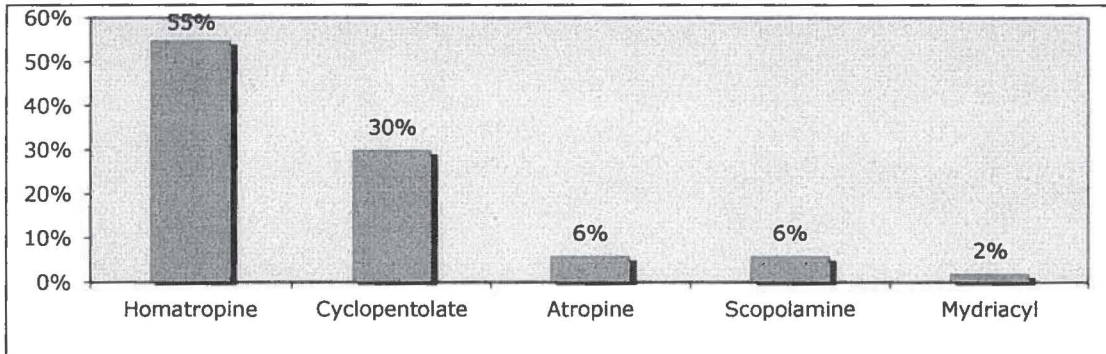


Figure 19. Corneal Metallic Foreign Body: Cycloplegic Agents. Margin of Error  $\pm 10.60\%$

Thirty-seven respondents reported that they would use a bandage contact lens after metallic foreign body removal; 31 respondents specified a contact lens brand with Acuvue Oasys (Vistakon) being the most frequently selected option (Figure 20).

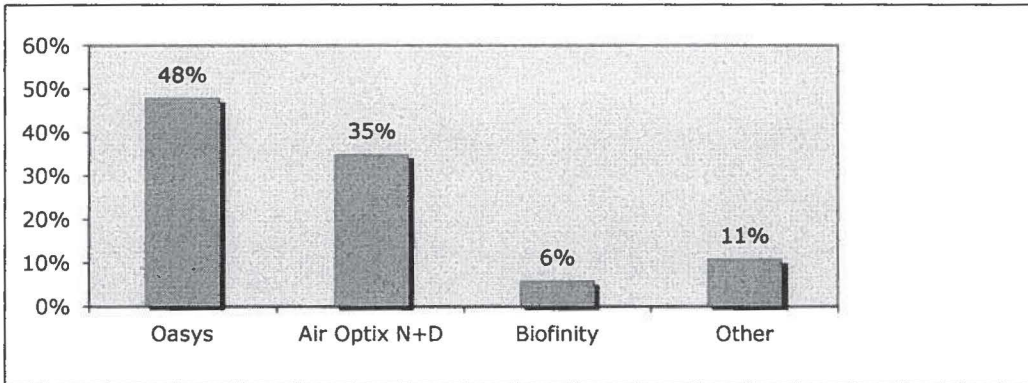
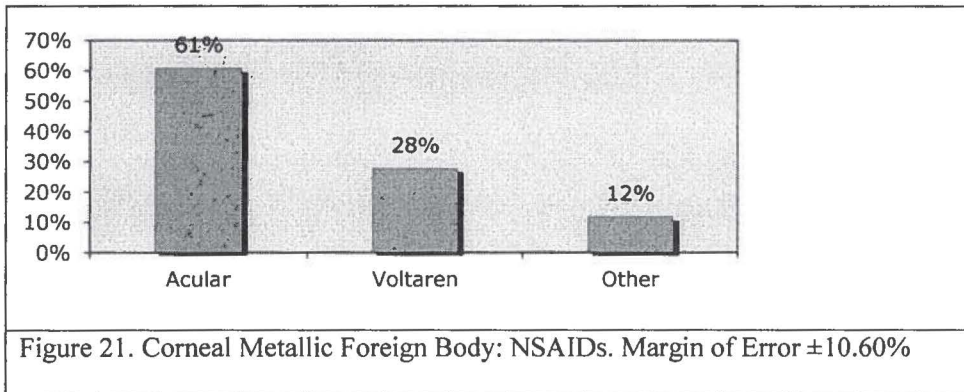


Figure 20. Corneal Metallic Foreign Body: Bandage Contact Lens. Margin of Error  $\pm 10.60\%$

Among the twenty respondents selecting a topical NSAID, there were eighteen specified agents including ketorolac tromethamine (Acular, Allergan, USA) (61%), diclofenac sodium (Voltaren, Novartis, USA) (28%), or other (12%) (Figure 21).



### *Discussion*

Implicit in the survey, although not directly addressed, is the removal of the foreign body from the cornea by the optometrist. Also implied in the question is that the foreign body injury is non-penetrating. Once the foreign body and rust ring have been removed, the injury is generally treated as a corneal abrasion. Corneal abrasions are typically treated with cycloplegia and dilated fundus exam to rule out complications, topical antibiotic, and pain control.<sup>22</sup>

#### *4.1 Topical Antibiotic*

As is the case with any bacterial infection, broad spectrum coverage is important unless treatment is selected based on culture and sensitivity studies. In the event of foreign body injuries, an antibiotic is generally used as a prophylactic measure. The most commonly selected treatment modality for corneal metallic foreign body was topical antibiotic, with

87% selecting antibiotic drop and 18% selecting antibiotic ointment. Four of the six specified antibiotic drops selected were fluoroquinolones, with moxifloxacin being the most frequent selection at 36%. The other two common responses were tobramycin and the antibiotic/steroid combination drop Tobradex at 15% and 10% respectively. The most commonly prescribed antibiotic ointments were tobramycin and bacitracin, each being selected by 27% of participants, while polytrim and erythromycin were also frequently selected.

#### *4.2 Pain Control*

Treatment modalities commonly selected for pain control include cycloplegia (47%), bandage contact lens (42%), artificial tears (38%), and topical NSAID (22%).

Respondents selected the longer-acting cycloplegic agents including homatropine (55%), cyclopentolate (30%), atropine (6%) and scopolamine (6%) while few opted to prescribe the shorter-duration cycloplegic mydracyl (2%). This survey does not address practitioners' reasons for the prescribing tendencies, and a review of the literature did not reveal that one cycloplegic is superior to another in the event of metallic foreign body, nor that cycloplegia is strictly required in all cases. The Handbook of Ocular Disease Management states that oral NSAIDs and rest are appropriate for corneal foreign body, but in the event of severe pain topical NSAIDs or a bandage contact lens may be useful.<sup>22</sup>

A small percentage of survey respondents stated that they would prescribe a pressure patch, but this treatment modality has fallen somewhat out of favor since the use of bandage contact lenses has increased. However, it has been suggested that some practitioners believe that a pressure patch will keep patients more still and restful.<sup>22</sup>

### *4.3 Bandage Contact Lens*

The benefits of a bandage lens for a corneal abrasion after removal of a metallic foreign body include increased patient comfort, enhanced rate of healing, and protection of the abrasion.<sup>23</sup> The bandage contact lens most commonly selected by respondents was the Acuvue Oasys (48%) lens with Air Optix Night & Day being second most commonly selected (35%) and Biofinity being selected the least (6%). Silicone hydrogel lenses are an excellent choice for a patient with corneal abrasion because of their high oxygen permeability and FDA approval for extended wear.<sup>23</sup> Silicone hydrogel lenses FDA approved for therapeutic use include Air Optix Night and Day Aqua (lotrafilcon A) (Alcon), PureVision (balafilcon A) (Bausch & Lomb), Acuvue Oasys (senofilcon A) (Vistakon), and Sof-Form 55 EW (methafilcon A) (Unilens Corp). Air Optix and PureVision lenses are approved for up to 30 days of extended wear, while Oasys and Sof-Form 55 EW are approved for 7 days of extended wear.<sup>23</sup> The approved lenses are generally considered equally effective, although a recent masked comparative study of lotrafilcon A and senofilcon A among PRK patients found an equal rate of reepithelialization and mean visual acuity but greater comfort in those patients assigned to senofilcon A lenses.<sup>24</sup> Other than patient comfort, a literature search did not reveal that one lens material is superior to another in terms of objective patient outcomes such as visual acuity or rate of healing.



*Instructional Module*

Based on the findings of the survey and literature review, sample prescriptions for three antibiotics, an antibiotic/steroid, and artificial tear agents were developed. The sample prescriptions may be found below in Figure 22.

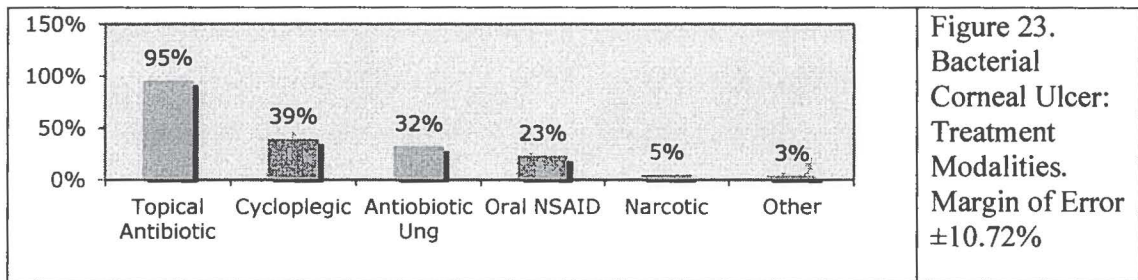
<p style="text-align: center;">University Eye Center 1124 S State Street Big Rapids, MI 49307</p> <hr/> <p>Name: _____ DOB: _____ Address: _____ Date: _____</p> <p><b>R</b> Acular ophthalmic soln - 3 mL bottle 1 qid up to qid OD x 3 days</p> <p><input type="checkbox"/> Label Refill: ___ 0 ___ times _____ O.D. _____ O.D. <small>*Label Number Permitted      Dispense as written</small></p>	<p style="text-align: center;">University Eye Center 1124 S State Street Big Rapids, MI 49307</p> <hr/> <p>Name: _____ DOB: _____ Address: _____ Date: _____</p> <p><b>R</b> Moxeza (moxifloxacin) ophthalmic soln 5 mL 1 drop tid OD x 3 days</p> <p><input type="checkbox"/> Label Refill: ___ 0 ___ times _____ O.D. _____ O.D. <small>*Label Number Permitted      Dispense as written</small></p>
<p style="text-align: center;">University Eye Center 1124 S State Street Big Rapids, MI 49307</p> <hr/> <p>Name: _____ DOB: _____ Address: _____ Date: _____</p> <p><b>R</b> Homatropine 0.4% ophthalmic soln 1 qid bid-4id OD x 3 days</p> <p><input type="checkbox"/> Label Refill: ___ 0 ___ times _____ O.D. _____ O.D. <small>*Label Number Permitted      Dispense as written</small></p>	<p style="text-align: center;">University Eye Center 1124 S State Street Big Rapids, MI 49307</p> <hr/> <p>Name: _____ DOB: _____ Address: _____ Date: _____</p> <p><b>R</b> Cyclopentolate 1% ophthalmic soln 1 qid bid-4id OD x 3 days</p> <p><input type="checkbox"/> Label Refill: ___ 0 ___ times _____ O.D. _____ O.D. <small>*Label Number Permitted      Dispense as written</small></p>
<p style="text-align: center;">University Eye Center 1124 S State Street Big Rapids, MI 49307</p> <hr/> <p>Name: _____ DOB: _____ Address: _____ Date: _____</p> <p><b>R</b> Polybryn ophthalmic ung Apply 1/2 inch ribbon to lower lid qd-bid OD</p> <p><input type="checkbox"/> Label Refill: ___ 0 ___ times _____ O.D. _____ O.D. <small>*Label Number Permitted      Dispense as written</small></p>	<p style="text-align: center;">University Eye Center 1124 S State Street Big Rapids, MI 49307</p> <hr/> <p>Name: _____ DOB: _____ Address: _____ Date: _____</p> <p><b>R</b> Bacitracin ophthalmic ung Apply 1/2 inch ribbon to lower lid qd-bid OD</p> <p><input type="checkbox"/> Label Refill: ___ 0 ___ times _____ O.D. _____ O.D. <small>*Label Number Permitted      Dispense as written</small></p>

Figure 22. Corneal Metallic Foreign Body: Sample Prescriptions

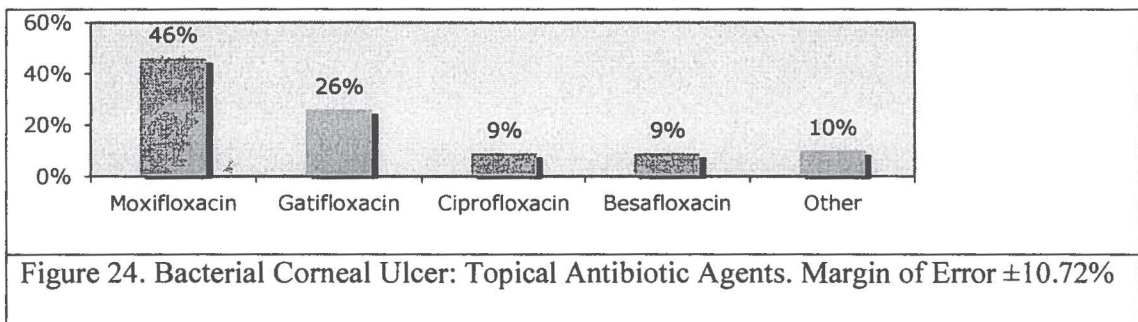
5. Instructional Module 5: Bacterial Corneal Ulcer

Results

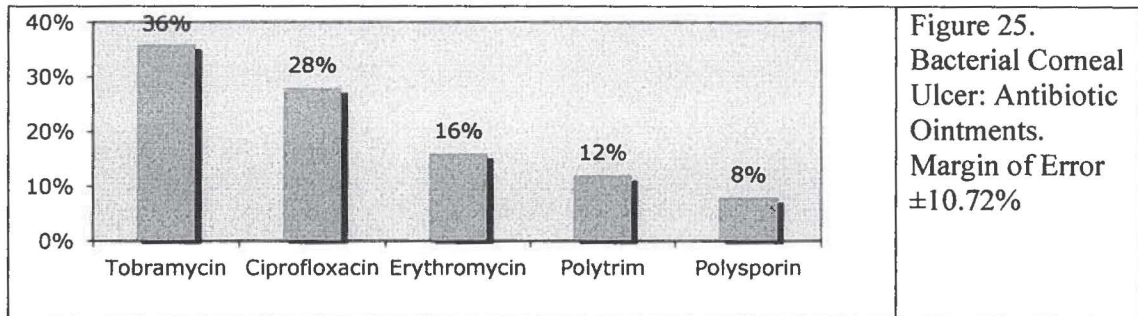
There were 87 respondents to the bacterial corneal ulcer questions, resulting in a conservative margin of error of 10.72%, providing a rough reflection of the confidence interval around each data point as discussed in the Methods section. When respondents were asked their preferred treatment modality for a 1mm corneal ulcer of bacterial origin, the majority stated that they would prescribe a topical antibiotic (95%). Other common responses included cycloplegic (39%), antibiotic ointment (32%), oral NSAID (23%), narcotic (5%), or other (3%) (Figure 23).



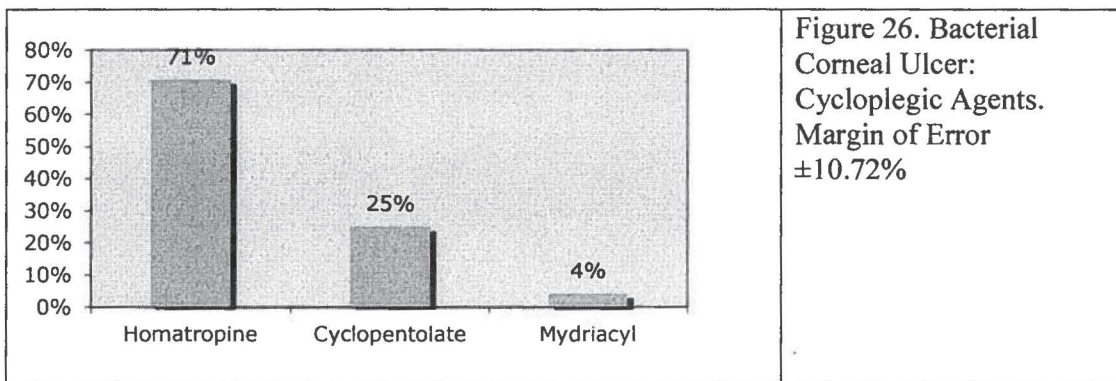
Among the 83 respondents selecting that they would prescribe a topical antibiotic, there were 99 antibiotic agents specified. The most common topical antibiotics selected by respondents include moxifloxacin (46%), gatifloxacin (26%), ciprofloxacin (9%), besafloxacin (9%), and other (10%) (Figure 24).



Among the 28 respondents reporting that they would prescribe an antibiotic ointment, there were 25 responses selecting a specific antibiotic ointment. The most common antibiotic ointment prescribed for a bacterial corneal ulcer included tobramycin (36%), ciprofloxacin (28%), erythromycin (16%), polytrim (12%), and polysporin (8%) (Figure 25).



Among the 34 respondents selecting that they would prescribe a cycloplegic agent, there were 24 responses selecting a specific agent. The cycloplegics most commonly prescribed by respondents included homatropine (71%), cyclopentolate (25%), and mydriacyl (4%) (Figure 26).



## *Discussion*

As is the case with any pathology with bacterial etiology, the empirically preferable route includes culture and identification of the causative strain and antibacterial sensitivity. However, cost constraints, time limitations, and availability of such diagnostic testing to primary care optometrists limits the feasibility of such an approach. Additionally, research has found that cultures do not always yield results. One study cited a range of 53-73% of positive findings in cultured corneal ulcers and states that a number of factors including the antimicrobial nature of topical anesthetic agents may influence culture results.<sup>25</sup> In general, a broad spectrum antibiotic is the first line treatment for corneal ulcers.

### *5.1 Topical Antibiotics*

The majority of respondents stated that they would prescribe an antibiotic, with 95% reporting that they would choose a topical antibiotic and 32% specifying that they would prescribe a topical antibiotic ointment. An overwhelming majority of respondents selected fluoroquinolones in the treatment of corneal ulcers, with nearly half (46%) prescribing the fourth generation fluoroquinolone moxifloxacin (sold under brand names Vigamox® or Moxeza® moxifloxacin HCl ophthalmic solution 0.5%; both products by Alcon). The distribution of antibiotic agents selected by respondents was similar to those found in the bacterial conjunctivitis section, with the exception that older broad spectrum antibiotics such as tobramycin and polytrim were prescribed in ointment form and not in the form of topical solution. In fact, 36% of respondents that opted to prescribe an

antibiotic ointment selected tobramycin, with the fluoroquinolone ciprofloxacin ointment being the second most commonly selected antibiotic ointment with a response of 28%.

A minority of respondents selected fortified antibiotics (presumably tobramycin-cefazolin), although a recent literature review found that 41% of corneal specialists prescribe a combination of fortified antibiotics and fourth-generation fluoroquinolones.<sup>26</sup> However, it may be possible that corneal specialists are using this combination therapy for the more severe cases that present to their offices, as only 12% of general ophthalmologists were found to prescribe fortified antibiotics in the same review.<sup>26</sup>

### *5.2 Pain Control*

A review of the literature provides little insight as to the most appropriate pain control modality for a patient suffering from a corneal ulcer. In this survey, 39% of respondents stated that they would prescribe a cycloplegic agent. Cycloplegics are considered an adjunctive therapy to help with pain and anterior chamber reaction if present.<sup>27</sup> The most commonly prescribed cycloplegic is homatropine (71%), although cyclopentolate (25%) and mydracyl (4%) were also selected. Participants in the survey also reported that they would prescribe oral NSAID's, narcotics, and other agents to aid in pain control. Some of the oral painkillers specified by participants included ibuprofen, extra strength acetaminophen, vicodin, Tylenol 3, and tramadol.

*Instructional Module*

Based on the findings of the survey and literature review, sample prescriptions for two antibiotics, a cycloplegic, and a painkiller were developed. The sample prescriptions may be found below in Figure 27.

<p style="text-align: center;">University Eye Center 1124 S State Street Big Rapids, MI 49307</p> <hr/> <p>Name: _____ DOB: _____ Address: _____ Date: _____</p> <p><b>Rx</b> Vigamox (moxifloxacin) ophthalmic soln 3 mL 2 gtt q1 3min for 3-3 hrs, then 1 gtt qbr 1-3 days. Then q2hr to significant resolution, then qid to day 14</p> <p><input type="checkbox"/> Label Refill: <u>  3  </u> times _____ O.D. _____ O.D. <small>*Federal Register Required      Dispense as written</small></p>	<p style="text-align: center;">University Eye Center 1124 S State Street Big Rapids, MI 49307</p> <hr/> <p>Name: _____ DOB: _____ Address: _____ Date: _____</p> <p><b>Rx</b> Tobramycin ophthalmic ung Apply 0.3 inch strip to lower lid bid OD x 14 days</p> <p><input type="checkbox"/> Label Refill: <u>  0  </u> times _____ O.D. _____ O.D. <small>*Federal Register Required      Dispense as written</small></p>
<p style="text-align: center;">University Eye Center 1124 S State Street Big Rapids, MI 49307</p> <hr/> <p>Name: _____ DOB: _____ Address: _____ Date: _____</p> <p><b>Rx</b> Homatropine 5% ophthalmic soln 1 drop tid-bid OD x 3 days</p> <p><input type="checkbox"/> Label Refill: <u>  0  </u> times _____ O.D. _____ O.D. <small>*Federal Register Required      Dispense as written</small></p>	<p style="text-align: center;">University Eye Center 1124 S State Street Big Rapids, MI 49307</p> <hr/> <p>Name: _____ DOB: _____ Address: _____ Date: _____</p> <p><b>Rx</b> Tylenol (acetaminophen) + codeine 50 mg PRN - q4h, as need for pain</p> <p><input type="checkbox"/> Label Refill: <u>  0  </u> times _____ O.D. _____ O.D. <small>*Federal Register Required      Dispense as written</small></p>

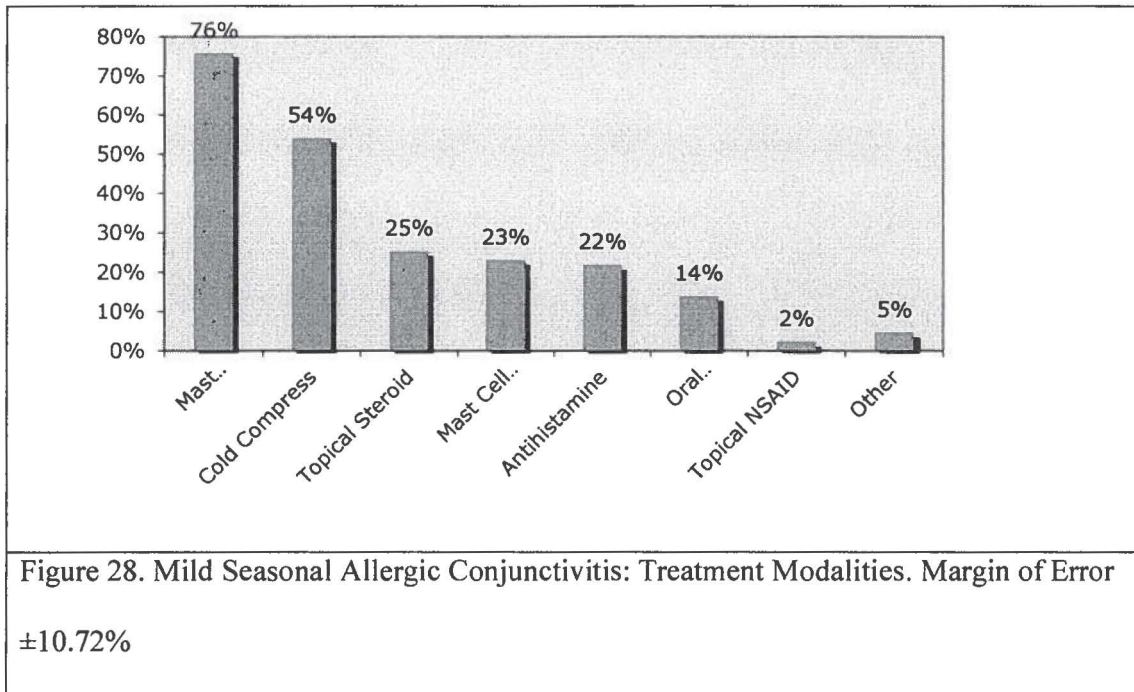
Figure 27: Bacterial Corneal Ulcer: Sample Prescriptions



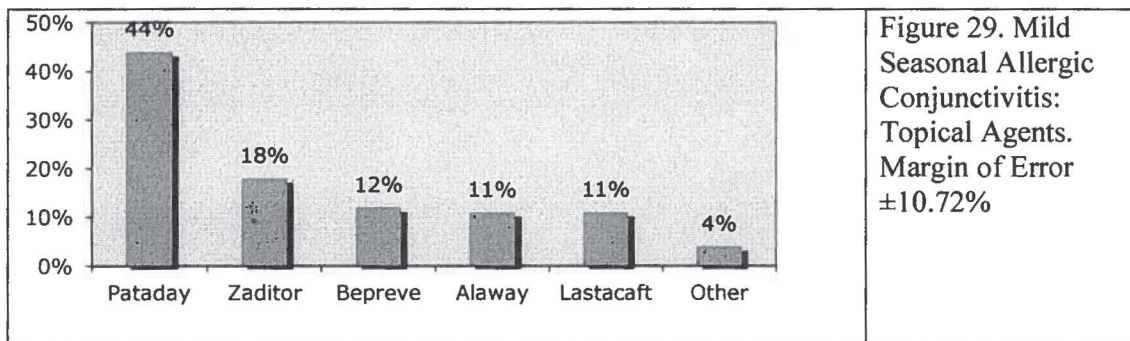
## 6. Instructional Module 6: Seasonal Allergic Conjunctivitis

### Results

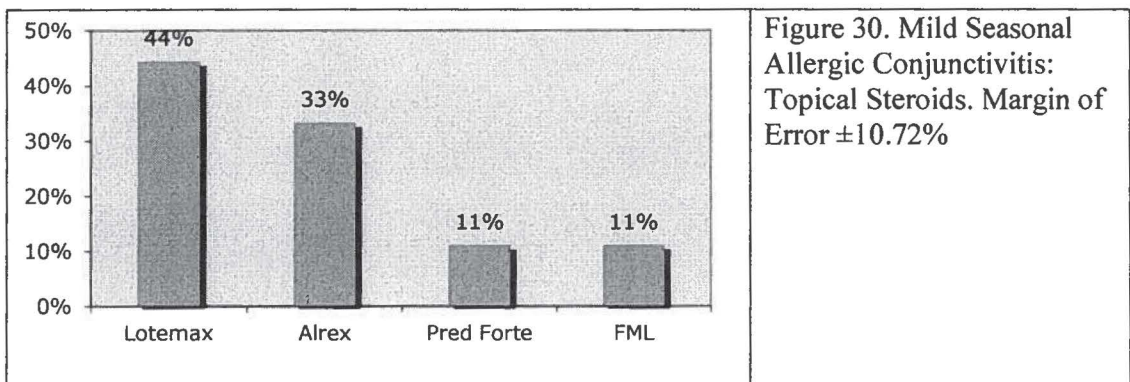
There were 87 respondents to the mild seasonal allergic conjunctivitis questions, resulting in a conservative margin of error of 10.72%, providing a rough reflection of the confidence interval around each data point as discussed in the Methods section. For patients suffering from ophthalmic manifestations of seasonal allergies, including seasonal allergic conjunctivitis, respondents reported that they would prescribe mast cell stabilizer/antihistamine combination agents (76%), cold compresses (54%), topical steroids (25%), mast cell stabilizers (23%), topical antihistamines (22%), oral antihistamine (14%), topical NSAID (2%), and other (5%) (Figure 28).



There were 149 agents selected when respondents were asked to specify the topical allergy treatment that they would prescribe. The topical agents ideally prescribed by respondents include olopatadine hydrochloride (Pataday, Alcon, USA) (44%), Zaditor (18%), bepotastine besilate (Bepreve, Bausch & Lomb, USA) (12%), ketotifen fumarate (Alaway, Bausch & Lomb, USA) (11%), alcaftadine (Lastacaft, Allergan, USA) (11%), and other (4%) (Figure 29).



There were twenty-seven responses provided by the twenty-two respondents reporting that they would prescribe a topical steroid to a patient suffering from mild seasonal allergic conjunctivitis. The topical steroids prescribed for mild ocular allergies include Lotemax (44%), Alrex (33%), PredForte (11%), and FML (11%) (Figure 30).





## *Discussion*

Antihistamines, mast cell stabilizers, and combination drops were the most widely used modalities for the treatment of ocular allergies amongst surveyed optometrists.

Antihistamines work as antagonists of the histamine receptors responsible for the initiation of the inflammatory cascade associated with allergic conjunctivitis.<sup>28-30</sup> Mast cell stabilizers, on the other hand, work earlier in the inflammatory pathway by preventing mast cells from degranulating and releasing histamine. Thus, mast cell stabilizers must be used at least two weeks prior to allergy season to be effective.<sup>28-30</sup>

Together, antihistamines and mast cell stabilizers work synergistically to block two branches of the allergy cascade, which explains the preference of 73% of surveyed optometrists for combination drugs as their first-line therapy. When choosing an appropriate allergy drop, optometrists have the choice between over-the-counter (OTC) and prescription medications.

### *6.1 Over-the-Counter Allergy Medications*

The two most common active ingredients in over-the-counter drops are Pheniramine maleate/Naphazoline (Naphcon-A, Alcon and Opcon-A, Bausch & Lomb) and Ketotifen fumarate (Zaditor and Alaway).<sup>31</sup> In the surveyed optometrists, the two most commonly used OTC allergy drops were Zaditor and Alaway. Although Naphcon-A and Opcon-A both have combination vasoconstriction agents included, they are associated with high rates of rebound hyperemia, leading to the preference for ketotifen.<sup>31</sup>

Over-the-counter allergy drops offer a cost-effective option to patients without insurance; however, most patients find prescription allergy drops more efficacious.<sup>31</sup> In fact, greater

than 85% of surveyed patients stated that they were not completely satisfied with OTC allergy drops.<sup>32</sup> Therefore, when cost is an issue, OTC drops offer a relatively cheap medication to trial, however, a change to a prescription medication may be necessary if satisfactory symptomatic relief is not provided.

### *6.2 Prescription Allergy Medications*

For prescription allergy medications, the optometrists surveyed by far most commonly preferred Pataday, followed by Bepreve and Lastacaft. Pataday and Lastacaft both offer the convenience of once-a-day dosing, while Bepreve is dosed twice-a-day. Despite the preference for Pataday amongst the optometrists in this study, another study conducted at the McCabe Vision Center found a 66.7% preference for Bepreve over Pataday amongst patients. In that study, Bepreve was found to provide superior evening symptomatic relief, while the effects of Pataday diminished in the evening hours.<sup>32</sup> Lastacaft was not included in the study, but Lastacaft has been proven to be effective as soon as 3 minutes after instillation in 97% of patients and for up to 16 hours in 87% of patients.<sup>33</sup>

For moderate to severe acute cases of allergic conjunctivitis, steroids are a useful short-term treatment option.<sup>29-30,34</sup> Whenever a steroid is used, careful monitoring for increased IOP, posterior subcapsular cataracts, and subsequent ocular infections must be employed. However, the advent of the “soft” ester-based steroid loteprednol etabonate has been a huge step in the steroid management of ocular allergies. Compared to ketone-based steroids, loteprednol results in less IOP elevation, since it is rapidly transformed to inactive metabolites after instillation.<sup>29-30,34</sup> This advancement likely accounts for the preference of surveyed optometrists for Lotemax (loteprednol etabonate 0.5%) and

Alrex (loteprednol etabonate 0.2%). A study conducted on 147 patients with allergic conjunctivitis and treated with loteprednol 0.2% four times per day found that none of the participants had a statistically significant increase in IOP.<sup>34</sup> Despite these results and advancements, most practitioners typically still only use steroids on a short-term basis for severe acute allergic reactions.<sup>29-30</sup>

### *6.3 Non-Pharmacologic Agents*

There are also many non-pharmacologic treatment options available to prevent the symptoms of allergic conjunctivitis. With the most obvious of these being avoiding the offending allergens through means such as hand washing, linen washing, wearing sunglasses outside for protection, closing windows, and other environmental modifications.<sup>29</sup> The judicious use of artificial tears can also help remove allergens and lubricate the eye.<sup>29-30</sup> Furthermore, fifty-four percent of surveyed optometrists recommend cold compresses to soothe patient symptoms. Finally, for contact lens wearers, daily disposable lenses help prevent allergen contamination on contact lenses by providing a fresh, deposit-free lens each day.<sup>29</sup>

*Instructional Module*

Based on the findings of the survey and literature review, sample prescriptions for antihistamine/steroid combinations, antihistamines, steroids, and an oral antihistamine were developed. The sample prescriptions may be found below in Figure 31.

<p style="text-align: center;">University Eye Center 1124 S State Street Big Rapids, MI 49307</p> <hr/> <p>Name: _____ DOB: _____ Address: _____ Date: _____</p> <p><b>R</b> Patisday ophthalmic solution 2.5 mL 1 qid qd OU</p> <p><input type="checkbox"/> Label Refill: ___/___/____ _____ O.D. _____ O.D. <small>*Medical Director: Permitted      Dispensed as written</small></p>	<p style="text-align: center;">University Eye Center 1124 S State Street Big Rapids, MI 49307</p> <hr/> <p>Name: _____ DOB: _____ Address: _____ Date: _____</p> <p><b>R</b> Aircas ophthalmic suspension 3 mL 1 qid qd OU x 2 weeks</p> <p><input type="checkbox"/> Label Refill: ___/___/____ _____ O.D. _____ O.D. <small>*Medical Director: Permitted      Dispensed as written</small></p>
<p style="text-align: center;">University Eye Center 1124 S State Street Big Rapids, MI 49307</p> <hr/> <p>Name: _____ DOB: _____ Address: _____ Date: _____</p> <p><b>R</b> Zaditor (bimatoprost) ophthalmic solution 1 drop bid OU</p> <p><input type="checkbox"/> Label Refill: ___/___/____ _____ O.D. _____ O.D. <small>*Medical Director: Permitted      Dispensed as written</small></p>	<p style="text-align: center;">University Eye Center 1124 S State Street Big Rapids, MI 49307</p> <hr/> <p>Name: _____ DOB: _____ Address: _____ Date: _____</p> <p><b>R</b> Latsacraft ophthalmic solution 1 drop qd OU</p> <p><input type="checkbox"/> Label Refill: ___/___/____ _____ O.D. _____ O.D. <small>*Medical Director: Permitted      Dispensed as written</small></p>
<p style="text-align: center;">University Eye Center 1124 S State Street Big Rapids, MI 49307</p> <hr/> <p>Name: _____ DOB: _____ Address: _____ Date: _____</p> <p><b>R</b> Loralene ophthalmic suspension 1 qid qd OU x 2 weeks</p> <p><input type="checkbox"/> Label Refill: ___/___/____ _____ O.D. _____ O.D. <small>*Medical Director: Permitted      Dispensed as written</small></p>	<p style="text-align: center;">University Eye Center 1124 S State Street Big Rapids, MI 49307</p> <hr/> <p>Name: _____ DOB: _____ Address: _____ Date: _____</p> <p><b>R</b> Lorastadine 10mg - 90 tablets 1 tablet po qd</p> <p><input type="checkbox"/> Label Refill: ___/___/____ _____ O.D. _____ O.D. <small>*Medical Director: Permitted      Dispensed as written</small></p>

Figure 31. Mild Seasonal Allergic Conjunctivitis: Sample Prescriptions

## 7. Instructional Module 7: Mild Anterior Uveitis

### Results

There were 87 respondents to the mild anterior uveitis questions, resulting in a conservative margin of error of 10.72%, providing a rough reflection of the confidence interval around each data point as discussed in the Methods section. Ideal treatment of mild anterior uveitis reported by respondents include topical steroid (97%), cycloplegic (76%), and other (2%) (Figure 32).

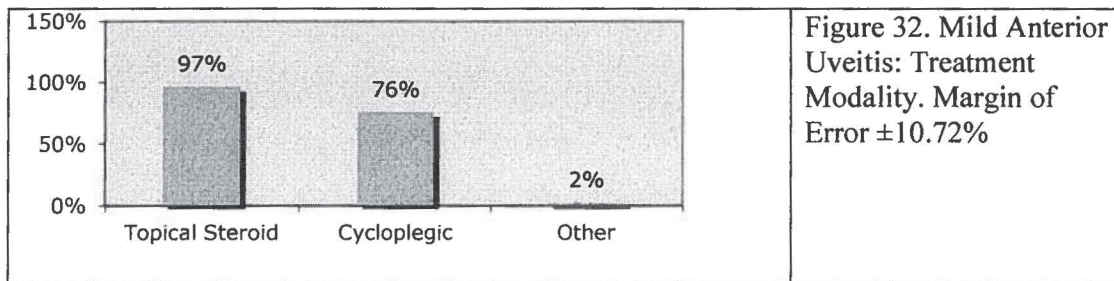


Figure 32. Mild Anterior Uveitis: Treatment Modality. Margin of Error  $\pm 10.72\%$

Among the eighty-four respondents selecting a steroid as part of treatment for anterior uveitis, there were 91 responses to preferred steroid with the majority of respondents selecting PredForte. The topical steroids preferred by respondents included PredForte (84%), Lotemax (8%), Durezol (5%), and FML (3%) (Figure 33).

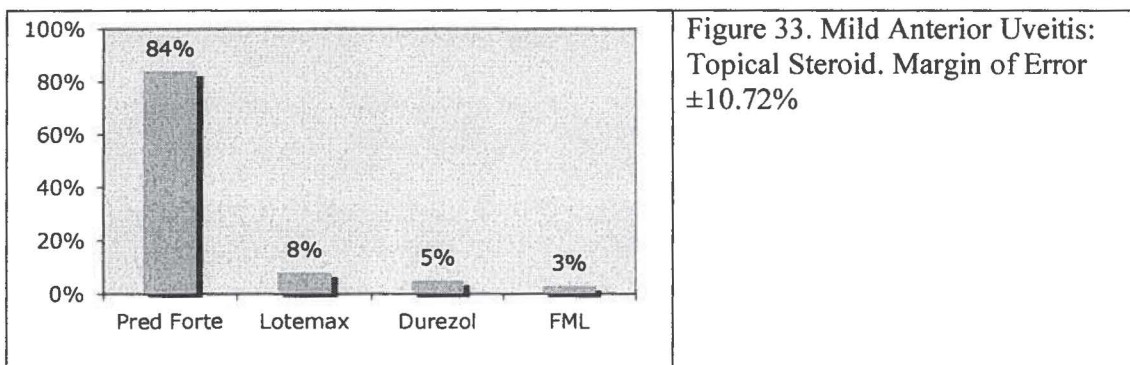
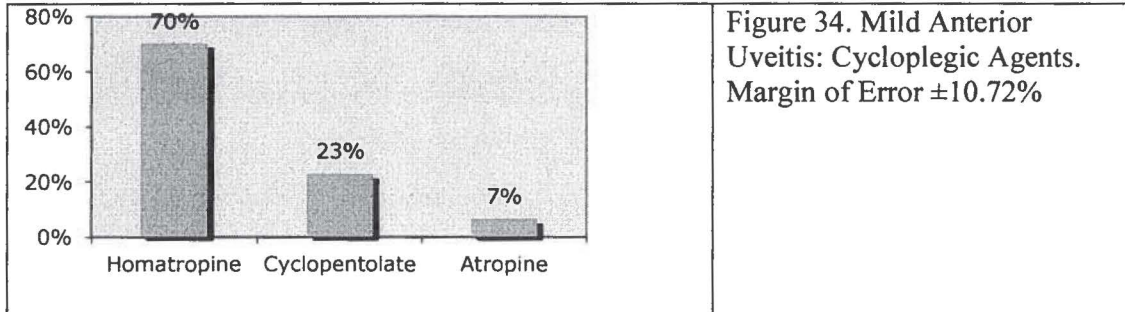


Figure 33. Mild Anterior Uveitis: Topical Steroid. Margin of Error  $\pm 10.72\%$

Sixty-six respondents reported that they would prescribe a cycloplegic agent, and there were 61 responses when respondents were asked to specify a cycloplegic agent to treat mild anterior uveitis. The cycloplegic agents ideally prescribed by respondents include homatropine (70%), cyclopentolate (23%), and atropine (7%) (Figure 34).



### *Discussion*

The primary goals in treating uveitis are to reduce inflammation and to reduce pain, often achieved by the use of steroids and cycloplegic agents. The treatment of uveitis may also include additional testing to rule out systemic associations as well as the treatment of coincident or secondary pathologies such as posterior synechiae, secondary glaucoma, or macular edema. Neither diagnostic tests nor treatment of secondary phenomena were addressed in the survey.

#### *7.1 Topical Steroids*

Topical steroids are the standard of care for treatment of anterior uveitis in the United States, and 97% of respondents report that they would prescribe a topical steroid for a patient with mild anterior uveitis. The majority (84%) of practitioners answering the survey responded that they would prescribe PredForte, specified by brand name in the

survey. Some participants responded that they would select a more mild steroid, with 8% and 3% prescribing Lotemax and FML, respectively.

Five percent of respondents selected the steroid emulsion difluprednate ophthalmic solution (Durezol®; Alcon Laboratories, USA). In a recent study, difluprednate administered four times per day was found to be as effective as PredForte (generic prednisolone acetate was not included in the study) prescribed eight times per day in a randomized study of 90 patients with anterior uveitis.<sup>35</sup> The potency of difluprednate is attributable to high glucocorticoid receptor binding affinity, superior tissue penetration, and enhanced bioavailability due to small emulsion droplet size and difluprednate particle solubility in the emulsion.<sup>35</sup>

## *7.2 Cycloplegics*

Any of the cycloplegics may be used in the treatment of anterior uveitis; 70% of respondents stated that they would prescribe homatropine, while 23% reported that they would prescribe cyclopentolate. Seven percent of respondents selected atropine. The AOA's Clinical Practice Guidelines state that atropine, homatropine, scopolamine, or cyclopentolate in a variety of concentrations are suitable cycloplegic agents for the treatment of anterior uveitis.<sup>36</sup> If cyclopentolate is prescribed, it should be dosed three times per day whereas homatropine may be dosed twice per day for mild anterior uveitis.<sup>36</sup> Due to its duration of action, atropine is typically reserved for moderate or severe anterior uveitis.<sup>36</sup> Phenylephrine should not be used as a cycloplegic because it has neither cycloplegic nor anti-inflammatory properties, although it may be used to aid in breaking synechiae.<sup>36</sup>

### *7.3 Other*

Two percent of respondents stated that they would prescribe some other treatment for anterior uveitis, specifying the oral NSAID ibuprofen. Ibuprofen is a prostaglandin inhibitor and may be useful in reducing inflammation and helping with pain control.



*Instructional Module*

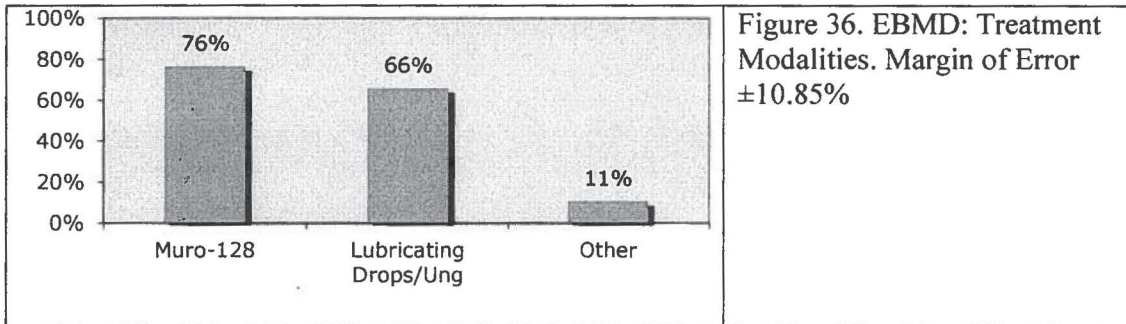
Based on the findings of the survey and literature review, sample prescriptions for two topical steroids, two cycloplegics, and an oral painkiller were developed. The sample prescriptions may be found below in Figure 35.

<p style="text-align: center;">University Eye Center 1124 S State Street Big Rapids, MI 49307</p> <hr/> <p>Name: _____ DOB: _____ Address: _____ Date: _____</p> <p><b>Rx</b> Pred forte ophthalmic suspension 9 mL 1 qid q1-2h QD x 1-2 days (then re-evaluate)</p> <p><input type="checkbox"/> Label Ref: ___/___/___ _____ Q.D. _____ Q.D. <small>*Federal Register Permitted      Dispense as written</small></p>	<p style="text-align: center;">University Eye Center 1124 S State Street Big Rapids, MI 49307</p> <hr/> <p>Name: _____ DOB: _____ Address: _____ Date: _____</p> <p><b>Rx</b> Homatropine 5% ophthalmic soln 1 qid QD x 1-2 days (then re-evaluate)</p> <p><input type="checkbox"/> Label Ref: ___/___/___ _____ Q.D. _____ Q.D. <small>*Federal Register Permitted      Dispense as written</small></p>
<p style="text-align: center;">University Eye Center 1124 S State Street Big Rapids, MI 49307</p> <hr/> <p>Name: _____ DOB: _____ Address: _____ Date: _____</p> <p><b>Rx</b> Cyclopentolate 1% ophthalmic soln 1 drop bid QD x 1-2 days (then re-evaluate)</p> <p><input type="checkbox"/> Label Ref: ___/___/___ _____ Q.D. _____ Q.D. <small>*Federal Register Permitted      Dispense as written</small></p>	<p style="text-align: center;">University Eye Center 1124 S State Street Big Rapids, MI 49307</p> <hr/> <p>Name: _____ DOB: _____ Address: _____ Date: _____</p> <p><b>Rx</b> Durezol ophthalmic emulsion 1 drop qid QD x 1-2 days (then re-evaluate)</p> <p><input type="checkbox"/> Label Ref: ___/___/___ _____ Q.D. _____ Q.D. <small>*Federal Register Permitted      Dispense as written</small></p>
<p style="text-align: center;">University Eye Center 1124 S State Street Big Rapids, MI 49307</p> <hr/> <p>Name: _____ DOB: _____ Address: _____ Date: _____</p> <p><b>Rx</b> Tylenol (acetaminophen) + codeine 60 mg PRN - qib, as needed for pain</p> <p><input type="checkbox"/> Label Ref: ___/___/___ _____ Q.D. _____ Q.D. <small>*Federal Register Permitted      Dispense as written</small></p>	

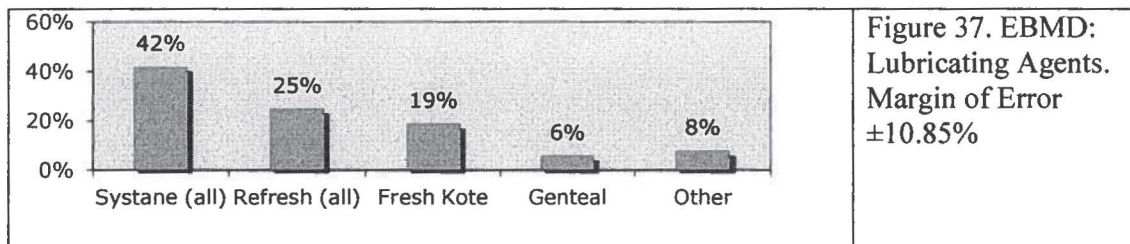
Figure 35: Mild Anterior Uveitis: Sample Prescriptions

8. Instructional Module 8: Epithelial Basement Membrane Dystrophy

There were 85 respondents to the epithelial basement membrane dystrophy questions, resulting in a conservative margin of error of 10.85%, providing a rough reflection of the confidence interval around each data point as discussed in the Methods section. For patients with epithelial basement membrane dystrophy (EBMD, Cogan's, map-dot-fingerprint dystrophy), respondents reported that they would ideally prescribe sodium chloride hypertonicity agents (Muro-128, Bausch & Lomb, USA) (76%), lubricating drops or ointment (66%), or other (11%). (Figure 36)



Fifty-six respondents reported that they would prescribe lubricating drops or ointment, and there were 72 responses when these respondents were asked to specify the lubricating agents preferred. Respondents showed some preference for Systane brand lubricating drops (42%) over Refresh (25%), FreshKote (Focus Laboratories, USA) (19%), Genteal (Alcon, USA) (6%), and other drops (8%) (Figure 37).



## *Discussion*

Although most patients with EBMD are asymptomatic, some patients presenting to optometric offices require treatment. The most common symptoms of EBMD are pain due to recurrent corneal erosion and blurred or distorted vision.<sup>37</sup>

### *8.1 Hypertonic Solution/Muro 128*

Seventy-six percent of respondents stated that they would prescribe hypertonic sodium chloride agents, specified in the survey as Muro-128. Hypertonic solutions are effective in decreasing epithelial edema which should increase epithelial adherence, thereby reducing epithelial heaping and recurrent erosions associated with EBMD.<sup>37</sup> Hypertonic ointments should be prescribed at bedtime, but may be applied every 3-4 hours if necessary. Hypertonic drops and ointments are both available over the counter, although it is helpful to write out a prescription to help the patient or their pharmacist find and use the appropriate medication. It should be noted that in one recent study, no significant difference was found between bland and hypertonic ointment used at night by patients with EBMD.<sup>37</sup>

### *8.2 Lubricating Drops or Ointment*

EBMD progression may result in an irregular corneal surface that wets poorly, leading to keratoconjunctivitis sicca.<sup>38</sup> As such, it is important to treat even asymptomatic patients with prophylactic support therapies including artificial tears, ointment, or other dry eye treatment modalities.<sup>38</sup> Additionally, patients complaining of associated blurred vision can be alleviated by lubricating drops throughout the day; a bland ointment may be

needed at night.<sup>37</sup> Of those surveyed, 66% of practitioners reported that they prescribe lubricating drops and/or ointment to patients diagnosed with EBMD.

When asked to specify the brand of lubricant used, the distribution of responses was similar to that found in the dry eye treatment section, suggesting some brand loyalty among practitioners. One exception, however, is that 19% of respondents specified that they would prescribe the new over-the-counter drop FreshKote, versus 5% of respondents specifying that they would prescribe FreshKote for patients suffering from dry eye.

FreshKote uses a unique and reportedly non-irritating preservative called polixetonium; the active ingredients in FreshKote are polyvinyl pyrrolidone and polyvinyl alcohol.<sup>39</sup> Product information published by the makers of FreshKote suggests a hypertonic treatment modality, reporting that the drop has high oncotic pressure with removes excess water from the epithelium, reduces microcystic edema, and helps to re-establish the integrity of the epithelium.<sup>39</sup> FreshKote has not been studied in pregnant women.

### *8.3 Other*

Although 11% of respondents selected “Other” in response to what they would prescribe for EBMD, none of these participants specified what they would prescribe. Research indicates that erythromycin or tetracycline ophthalmic ointment may be used at night to reduce matrix metalloproteinase-9, which has been implicated in recurrent corneal erosions.<sup>38</sup> Bandage contact lenses may be used, but clinicians must remember the risk of infection with prolonged use which would be expected for those suffering from recurrent corneal erosions.<sup>38</sup> For chronic recurrent erosions, patients may need to be referred to a

corneal specialist for debridement and diamond burr polishing or anterior stromal puncture if the erosion is below the visual axis.<sup>38</sup>

*Instructional Module*

Based on the findings of the survey and literature review, sample prescriptions for two hypertonic agents and two types of artificial tears were developed. The sample prescriptions may be found below in Figure 38.

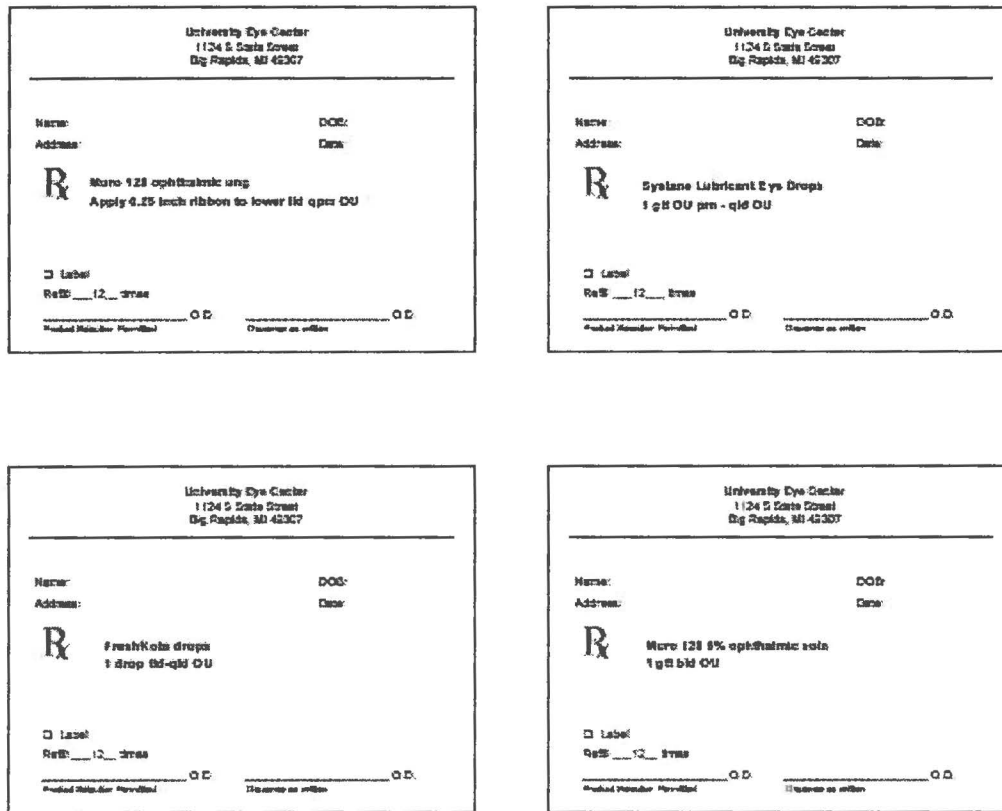


Figure 38. EBMD: Sample Prescriptions

## CONCLUSION

This survey was developed with the intention of defining commonly prescribed treatment modalities for some common anterior segment conditions to aid in the development of a clinical instructional module. The results, along with a literature review, were used to develop a sample prescription pad for optometry students, which may be found embedded in the text of the article.

The survey asked practitioners to specify the agents that they would prescribe if not limited by concerns related to insurance coverage, patient allergy, or other dilemmas faced by clinicians in daily practice. While this approach is excellent for development of a module used for academic purposes, it does not address issues such as the use of generic substitutes or cost considerations. Future research may be necessary to include such practical issues, as well as the development of a clinical instructional module for any number of other diagnoses or for pre- and post-operative treatment regimens.

## REFERENCES

1. Gilbard JP. Dry Eye – Natural History, Diagnosis and Treatment. Dec 2006.  
Available at: [http://www.dryeyeinfo.org/Dry\\_Eye\\_In\\_Depth.htm](http://www.dryeyeinfo.org/Dry_Eye_In_Depth.htm).
2. Diaz-Valle D, Arriola-Villalobos P, Garcia-Vidal SE, et al. Effect of lubricating eyedrops on ocular light scattering as a measure of vision quality in patients with dry eye. *J Cataract Refract Surg* 2012;38:1192-1197.
3. Pressner A. 6 Effective Dry Eye Treatments. FoxNews. 2012 Apr 6. Available at: <http://www.foxnews.com/health/2012/04/05/6-effective-dry-eye-treatments/>.
4. Melton R and Thomas R. Beneath the Surface of Dry Eye Disease. *Review of Optometry*. 2011 May 15:12A-15A.
5. Robin S. Fish Oil Dosages for Dry Eye. LiveStrong. Dec 2010. Available at: <http://www.livestrong.com/article/335320-fish-oil-dosages-for-dry-eyes/>
6. Highlights of Prescribing Information – Restasis. Allergan. Dec 2012. Available at: [http://www.allergan.com/assets/pdf/restasis\\_pi.pdf](http://www.allergan.com/assets/pdf/restasis_pi.pdf)
7. Bowling E and Russell GE. Topical Steroids and the Treatment of Dry Eye. *Review of Cornea and Contact Lenses*. 2011 Mar 3. Available at: [http://www.reviewofcontactlenses.com/content/d/dry\\_eye/c/27245/](http://www.reviewofcontactlenses.com/content/d/dry_eye/c/27245/).
8. Li M, Wang J, Shen M, et al. Effect of Punctal Occlusion on Tear Menisci in Symptomatic Contact Lens Wearers. *Cornea*. 2012;31:1014-1022.

9. Gupta C and Chauhan A. Ophthalmic Delivery of cyclosporine A by punctual plugs. *Journal of Controlled Release*. 2011;150:70-76.
10. Yoo S, Lee D, Chang M. The Effect of Low-Dose Doxycycline Therapy in Chronic Meibomian Gland Dysfunction. *Korean Journal of Ophthalmology*. 2005; 19(4):258-263.
11. Doxycycline. Drug Information Online. 2012 Mar 20. Available at: <http://www.drugs.com/doxycycline.html>.
12. Skevaki CL, Galani IE, Pararas MV, Giannopoulou KP, Tsakris A. Treatment of viral conjunctivitis with antiviral drugs. *Drugs*. 2011;7(3):331-347.
13. Wilkins MR, Khan S, Bunce C, Khawaja A, Siriwardena D, Larkin DFP. A randomized placebo-controlled trial of topical steroid in presumed viral conjunctivitis. *Bri J Ophthalmol*. 2011;95:1299-1303.
14. Kaufman HE. Adenovirus advances: new diagnostic and therapeutic options. *Curr Opin Ophthalmol*. 2011;22:290-3.
15. Goldman DA, Patel R. Pros and cons of topical steroids for viral conjunctivitis. *Cataract & Refractive Surgery Today Europe*. 2011;Sept:22-23.
16. Gupta D. Managing viral conjunctivitis: a primer. *Optometric Management*. 2003;Nov.
17. Patwardhan A. Topical ciprofloxacin can delay recovery from viral ocular surface infection. *J R Soc Med*. 2005;98:274-5.
18. Sambursky R, Trattler W, Tauber S, Starr C, Friedberg M, Boland T, McDonald M, DellaVecchia M, Luchs J. Sensitivity and specificity of the AdenoPlus test for diagnosing adenoviral conjunctivitis. *JAMA Ophthalmol*. 2013;131(1):17-22.



19. RPS Pathogen Screening, Inc. Reimbursement billing guide. 2012. Available at:  
<http://www.rpsdetectors.com/en/wp-content/uploads/2012/07/FORM-MKT-006.1-Reimburse-Billing-Guideshort.pdf>.
20. Sowka JW, Gurwood AS, Kabat AG. Acute Bacterial Conjunctivitis. *The Handbook of Ocular Disease Management*. 2011 Apr 15:16A-18A.
21. Muckley ED. Are We Gaining Ground on Ocular Infection? *Review of Optometry*. 2012 Dec 15:36-40.
22. Sowka JW, Gurwood AS, Kabat AG. Corneal Abrasion and Recurrent Corneal Erosion. *The Handbook of Ocular Disease Management*. 2011.
23. Gromacki S. The case for bandage soft contact lenses. *Rev Cornea & Contact Lenses*. 2012 January.
24. Razmjoo J, Abdi E, Atashkadi S, Reza AM, Reza PA, Akbari M. Comparative study of two silicone hydrogel contact lenses used as bandage contact lenses after photorefractive keratectomy. *Int J Prev Med*. 2012;3(10):718-722.
25. Maske R, Hill JC, Oliver SP. Management of bacterial corneal ulcers. *Br J Ophthalmol*. 1986;70:199-201.
26. Amescua G, Miller D, Alfonso EC. What is causing the corneal ulcer? Management strategies for unresponsive corneal ulceration. *Eye*. 2012;26:228-236.
27. Reed KK. How to manage bacterial eye infections. *Rev Optom*. 2011; May. Available at [http://www.revoptom.com/continuing\\_education/tabviewtest/lessonid/107608/](http://www.revoptom.com/continuing_education/tabviewtest/lessonid/107608/).
28. Figus M, Fogagnolo P, Lazzeri S, et al. Treatment of allergic conjunctivitis: results of a 1-month, single-masked randomized study. *European Journal of Ophthalmology*. 2010; 20(5):811-818.

29. Bilkhu PS, Wolfsohn JS, Naroo SA. A review of non-pharmacological and pharmacological management of seasonal and perennial allergic conjunctivitis. *Contact Lens and Anterior Eye*. 2012; 35:9-16.
30. Bielory BP, O'Brien TP, Bielory L. Management of Seasonal Allergic Conjunctivitis: Guide to Therapy. *Acta Ophthalmologica*. 2012; 90:399-407.
31. Goldman DA. Over-the-counter drops for the treatment of Ocular Allergy. *Ophthalmology Web*. 20 Mar 2012.
32. McCabe CF, McCabe SE. Comparative efficacy of bepotastine besilate 1.5% ophthalmic solution versus olopatadine hydrochloride 0.2% ophthalmic solution evaluated by patient preference. *Clinical Ophthalmology*. 26 Oct 2012; 6:1731-1738.
33. Lastacaft Takes Allergan Back to its Roots. *Review of Ophthalmology*. 2 Feb 2011.
34. Gong L, Sun X, Qu J, et al. Loteprednol Etabonate Suspension 0.2% Administered QID Compared with Olopatadine Solution 0.1% Administered BID in Treatment of Seasonal Allergic Conjunctivitis: A Multicenter, Randomized, Investigator-masked, Parallel Group Study in Chinese Patients. *Clinical Therapeutics*. June 2012; 34(6):1259-1272.
35. Foster CS, DaVanzo R, Flynn TE, McLeod K, Vogel R, Crockett RS. Durezol (difluprednate ophthalmic emulsion 0.05%) compared with Pred Forte 1% ophthalmic suspension in the treatment of endogenous anterior uveitis. *J Ocular Pharm and Therapeutics*. 2010;26(5):475-483.
36. Alexander KL, Dul MW, Lalle PA, Magnus DE, Onofrey B. Optometric clinical practice guideline: care of the patient with anterior uveitis. St. Louis: American Optometric Association. 2004:1-38.

37. Laibson PR. Recurrent corneal erosions and epithelial basement membrane dystrophy. *Eye & Contact Lens*. 2010;36(5):315-317.
38. Sowka JW, Gurwood AS, Kabat AG. Epithelial Basement Membrane Dystrophy. *The Handbook of Ocular Disease Management*. 2011.
39. FreshKote product information, revised 05/2011, available at [http://www.freshkote.com/about-freshkote\\_5000\\_ct.aspx](http://www.freshkote.com/about-freshkote_5000_ct.aspx).