

USE OF THE KOWA RC-2 FUNDUS CAMERA

Jeffrey W. Lozen
April 19, 1983

INTRODUCTION

This paper will discuss the operation of the Kowa RC-2 fundus camera in a clinical setting. I have found the Kowa to be an extremely versatile means of photodocumentation. Being hand held, it can be transported easily to satellite locations. It can take adnexal, anterior segment, and fundus photographs. Also, being moderately priced, it would be a good first choice for the practitioner interested in providing ocular photography as an additional patient service.

Initially, an explanation of the camera and basic photographic technique will be presented. Secondly, the factors contributing to good photography will be explored. These include variables such as film speed, illumination, magnification, patient dilation and pigmentation, and fixational stability. Thirdly, special photographic techniques such as stereoscopic photography, use of filters for fluorescein enhancement and sequential fundus mapping will be detailed. Lastly, common photographic errors will be shown, and a guideline for (ocular) photography presented.

CAMERA BACKGROUND

The Kowa RC-2 is a mydriatic fundus camera which utilizes standard 35mm. slide film. A 22mm. photographic image is imprinted on the film which eliminates peripheral distortions found on a full 35mm. image. The camera takes a maximal field of view of 30° which is standard for non-contact fundus cameras. It operates at a shutter speed of 1/750th of a second which eliminates blur due to camera movement.¹

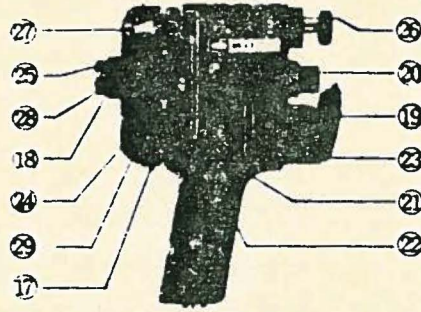
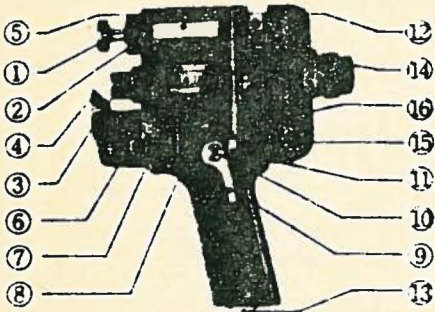
The camera is hand held and has an incorporated strobe flash with variable settings. Also, a built-in spotting illumination beam provides operator viewing of the target area. Extra features include a slide numbering system, a 2X internal magnification option, interchangeable film magazines, filter system for fluorescein photography, a 2.7X magnification oversert, a head stand mount, and a portable carrying case.² Figure 1 illustrates the controls and appearance of the Kowa RC-2.³

The camera has the distinct advantage of portability over the standard table mounted fundus cameras. Also, it is reasonably priced at approximately \$3000.00 for the camera and case. The head stand mount runs an additional \$600-700.⁴ The camera does have the limitation of mandatory dilation for fundus photography. Also, its built-in spotting illumination system is extremely bright, causing patient discomfort and a compromised focusing time for retinal documentation. When used in the hand held mode, operator technique is an important factor in producing well-centered and in-focus photographs. This technique must be practiced to reduce its effect on the quality of photography. Lastly, due to the re-

FIGURE 1

Names of Each Parts

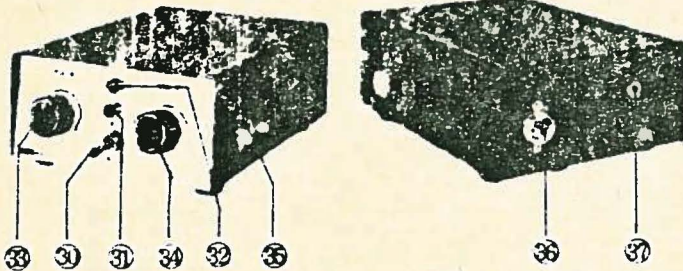
Camera Body




Camera Body

- ① Forehead Stabilizer
- ② Adjusting Knob for stabilizer
- ③ Objective Lens
- ④ Illuminating Prism
- ⑤ Focusing Scale
- ⑥ Shoe for Stand
- ⑦ Focusing Wheel
- ⑧ Lamp House
- ⑨ Shutter Lever
- ⑩ Holder for shutter lever
- ⑪ Synchro Terminal
- ⑫ Lock for dismounting camera back
- ⑬ Cord Socket
- ⑭ Photo Number Change Button
- ⑮ Knob for film winding
- ⑯ Button for film rewinding
- ⑰ Back Cover Opening Knob
- ⑱ Ring for Diopter Adjustment
- ⑲ Focusing Wheel
- ⑳ Knob for magnification change
- ㉑ Connection for shutter lever
- ㉒ Shutter Lock
- ㉓ Window for photo number
- ㉔ Film Counter
- ㉕ Film Winding Indicator
- ㉖ Connection for eye fixation lamp rod
- ㉗ Rewinding Crank
- ㉘ Film Plane Mark
- ㉙ Winding Knob

Standard Power Pack



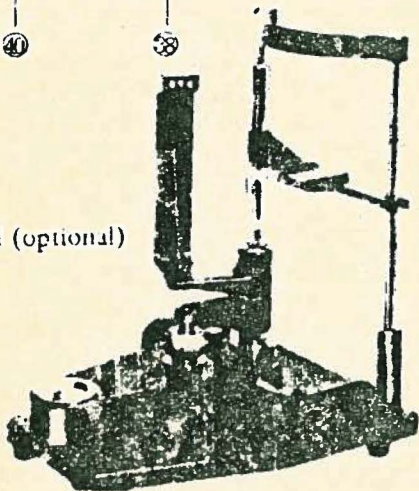
Connecting Cords



Standard Power Pack

- ⑳ Main Switch
- ㉑ Pilot Lamp for main switch
- ㉒ Charging Lamp for strobo flash
- ㉓ Volume Knob for illuminating lamp
- ㉔ Volume Knob for strobo-flash
- ㉕ Socket for camera cord
- ㉖ Socket for power pack cord
- ㉗ Change over box for primary voltage

Stand (optional)



Connecting Cords

- ㉘ Camera Cord
- ㉙ Connector for camera
- ㉚ Connector for power pack
- ㉛ Power Pack Cord
- ㉜ Plug for AC power source
- ㉝ Connector for power pack
- ㉞ Tip for grounding cord

duced cost of the system, photographic quality may not be comparable to the more expensive table mounted models.⁵ However, despite these drawbacks, adequate documentation can be attained.

PREPARING FOR PHOTOGRAPHY

Before any photos are taken, the operator should run through a check-list which will help eliminate poor photographs due to improper camera adjustments. One such list might read as follows:

- 1) Be sure viewing illumination and flash units are both functional and all bulbs are working
- 2) Proper slide number has been advanced onto slide
- 3) Magnification and flash settings are correct for the particular distance and type of shot
- 4) Proper distance has been preset prior to photography
- 5) Film has been wound
- 6) Full patient identification has been entered into the film log for future referencing

The operator should also have the patient sign a photography release form.^{6,7} This is legally important especially when full face photographs will appear in lectures or published material. Figure 2 gives an example of such a release.⁶

BASIC TECHNIQUE

The Kowa can be used in two modes: hand held or stand mounted. Only the hand held mode will be addressed at this point. Using the camera in the hand held position is very similar to using a monocular indirect ophthalmoscope. Use the right hand to hold the camera and the left hand to brace against the forehead. This will give additional control of focusing prior to shooting.

FIGURE 2

INFORMED CONSENT FOR EYE PHOTOGRAPHY

I, _____, hereby consent to photography of my eyes and/or associated areas for the documentation and/or diagnosis of any eye conditions or disease which may be present.

I understand that the photographs may be used to document my ocular status as well as for future use in any publications or educational presentations which may or may not benefit me.

Signed _____

Witness _____

Date _____

FIG. 5. Example of the consent form used in ocular photography.

417 EASTWAY DRIVE
CHARLOTTE, N. C. 28204
Telephone: 336-3344

PERMIT FOR PHOTOGRAPHY

I, the undersigned, authorize Dr. D. J. [redacted] to publish photograph(s) of me or _____ as he may desire in professional journals and books in the interest of education and research.

Further authority is given to publish information relating to the case either separately or in connection with the publication of the photograph(s) taken of me or _____.

Although I give permission for the publication of the aforementioned photograph(s) and information, it is specifically understood that I will not be identified by name.

Date _____

Signature _____

Witness _____

FIG. 2. Permit for Photography Form.

The parameters such as illumination, distance, and flash should all be preset prior to any exposure, and they will be discussed in more depth later. This eliminates all movement except focusing by moving toward or away from the patient and releasing of the shutter. Initially, this can be very difficult and only by practice will better technique be achieved.

Adnexal or anterior segment photography is easier than fundus photography and should be mastered first. Refer to table 3 and preset the distance, magnification, and flash intensity for the particular structure you are photographing. Preset the viewing beam as low as possible yet keep a good image of the target. Slowly move the camera toward the target until it is clearly focused. A trick is to use the corneal light reflex or other fine structure as a key for focusing. Try to release the shutter smoothly without jerking the camera body. As a rule, try to take two photos of any one anomaly. This is a good precaution against a blink or eye movement and gives a second slide in case a referral slide has to be sent out. Be sure the patient has an adequate target on which to steadily fixate. This target should be behind you and slightly above a straight ahead primary gaze.

Fundus photography is more difficult and requires patient dilation. Subsequently, the patient is more photophobic and will tend to avoid the light, tear, and generally make it harder to get good photographs. Allow 20-30 minutes for maximal dilation and be sure the patient has a good fixation target behind you to concentrate on. Again, refer to table 3 for presetting magnification and flash intensity. The distance scale will be set at zero for most fundus shots.

To find the retina, initially look for a red reflex at a distance of 6-8". Then move in toward the patient until the retina fills the field of view.² Now use the focusing wheel to fine-tune the focus (refer to figure 1). Use fine detail such as the vascular pattern to key the focusing. A camera to eye distance of 7mm. is the best for fundus photos^{1,3} and care must be taken to keep the illuminating prism from inadvertently contacting the cornea.

The intensity of the viewing illumination beam should be kept as dim as possible to avoid as much of the lid spasming and photophobia as possible. A good image must come through the viewfinder and this entails more light on the retina. Therefore a compromise is necessary between the two. To help control the lid reactions, use a finger of the bracing hand to hold the upper lid against the superior orbital rim. Have the patient place his finger on the cheekbone and pull down and out. This will pull the lower lid away yet leave you enough room to manipulate the camera at a close distance. The whole motion should be very fluid with little time delay. This will ensure proper focus with minimum patient discomfort.

FILM AND DEVELOPING

It is important to use quality film which will give consistent color rendition and contrast. Also, by using only one film type, comparative photographs taken at a later date will be more diagnostic. Kodak Ektachrome has proven to be the film of choice.^{3,5,6} Not only does it consistently give good results, but it also can be developed by most laboratories or even at home or in the office.

Film speed is also an important aspect which must be considered. Film speed is calibrated in terms of ASA ratings. A high ASA number

means the film is more sensitive to light but at the expense of being somewhat grainier. A low ASA gives greater resolution due to being very finely grained but is less sensitive to light and needs a brighter flash.⁶ Obviously, there is a balance point between the factors of light sensitivity and graininess of film resolution.

Table 1 outlines the effects of film speed, distance from the target, magnification and illumination. The table shows adequate adnexal shots could be taken with both 200 and 64 ASA film. (See slides 61 - 140). The 25 ASA film was not light sensitive enough to give adequate photographs over a reasonable distance range. (See slides 141 - 180). Also, a reddish tinge was prominent using this Kodachrome 25 ASA film. Distance becomes a critical factor in choosing a film speed. At 20cm., only the 200 ASA film was light sensitive enough to give adequate photos. At 10cm., the 200 and the 64 ASA film speeds were adequate. At 5cm., all the film speeds gave good photographs.

Fundus photography was done using the 200, 160, and 64 ASA film speeds. All film types gave adequate fundus shots at 1X magnification. However, as the magnification increased to 2X, the 64 ASA film was not light sensitive enough to give the best possible photographs. However, for fine detail, 64 ASA gives better resolution at lower magnification. (See slides 181 - 241).

Developing is also a key factor in the final quality of the photographs. It is essential to use one developer continuously to maintain consistent color rendition and contrast.⁷ Slides 1 - 4 demonstrate the variability which can occur due to different developers. Try to utilize a good photographic laboratory such as the Kodak laboratories.

ILLUMINATION AND DISTANCE

At the close working distance most ocular photography is done within; the flash intensity is the only illumination which plays a role in target illumination.⁶ Room illumination essentially plays no part in the final photographic results, and need not be controlled as a variable.

Table 1 shows the interplay between film speed, illumination, magnification and target to camera distance. Each film speed was tested with all the flash intensity settings at distances of 20, 10, and 5cm. The magnification was also changed from 1X to 2X at these distances and the flash intensity varied.

This bracketing of illumination intensities leads to some general conclusions. For adnexal photography, note how as the distance increases, more light is needed for adequate photos. Also, as magnification is increased, more light must be used to give consistent photography.

The same bracketing technique was utilized for fundus photography. The variables included magnification, film speed, and flash intensities. The major point to note was that patient coloration and pupil dilation played a major role in the quality of the photography. The results were again tabulated and summarized in table 1. (See slides 181 - 220). Note how light skinned, blonde fundus pictures required somewhat less flash intensity than dark skinned or black fundus photos.

PUPIL DILATION

This is the most critical factor in fundus photography. The Kowa RC-2 requires maximal dilation for best results. It has been

shown that an 8mm. pupil is the ideal size.^{3,5,8} This will allow a 30° view of the fundus and reduce photographic artifacts.

Before dilation the patient should undergo a screening to minimize possible adverse reactions. The angles should be evaluated via the Von Herick slit lamp technique, internal ocular pressures recorded, and a cursory slit lamp scan performed to rule out iris neovascularization. Also, a brief case history regarding prior dilation and allergic reactions is necessary. For the purposes of this paper, the standard sequence of drugs used for mydriasis was as follows: 1 drop Alcaine O.U., 1 drop of ½% Mydriacyl O.U., and lastly 1 drop of 2½% Neosynephrine O.U. In most cases this gave adequate dilation within a 20-30 minute time span. Marbourg⁶ has recommended the following drug regimen:

- 1) Infants and adolescents
 - a. 1 gtt. 1% Ophthaine
 - b. 1 gtt. 1% Cyclogel
 - c. Repeat in 15 minutes if needed
- 2) Adults: light irides
 - a. 1 gtt. 1% Ophthaine
 - b. 1 gtt. ½% Mydriacyl
 - c. Repeat in 15 minutes if needed
- 3) Adults: dark irides
 - a. 1 gtt. 1% Ophthaine
 - b. 1 gtt. 1% Mydriacyl
 - c. Repeat in 15 minutes if needed

Initial usage of Ophthaine prior to instillation of the mydriatic agent increases the amplitude and decreases the time of onset of the pupillary response. It is believed this effect is due to altered corneal permeability.⁹ Another effect is reduced corneal sensitivity. Thus, the burning and tearing is much reduced when the mydriatic agent is instilled and less dilation takes place.

Another factor which controls dilation is the pigmentation of the patient. A fair skinned individual will initially show a

more dramatic response to the dilating agents. The pigment in a black skinned individual partially absorbs the dilating drugs and therefore a lessened response is initially noted. However, the drugs are slowly released from the pigment granules thus increasing the chance for systemic reactions. Compare slides 20 (medium pigmentation), 56 (light pigmentation), and 197 (dark pigmentation). The first two slides had adequate dilation and give good field of view and fundus detail. However, the series of slides from 194-198 show the difficulty in obtaining good fundus photographs in a poorly dilated pupil. A second drop of 1% Mydriacyl may be instilled 20 minutes after the first sequence of drops if dilation is not adequate. Watch for a delayed response in dark-skinned patients due to the absorption of drug and subsequent release by the pigment granules.

Be sure the patient understands the time response for the dilating agent used. The patient should know how long the drug will affect his pupil and any possible side reactions that may occur. Lastly, be sure to dispense a disposable pair of mydriatic sunglasses especially on sunny days or in situations where the patient must drive home.

USING THE HEAD STAND

The major disadvantage in using the camera in a hand held mode is the inability to control spurious movements both of the patient and of the camera operator. The head stand eliminates these movements and thus gives much more precision in focusing and in general better photographs. This advantage is especially important when high magnification photography is being done. A stable eye and a fixed camera allow the critical focusing necessary in high magnification of ocular structures.

FIGURE 3

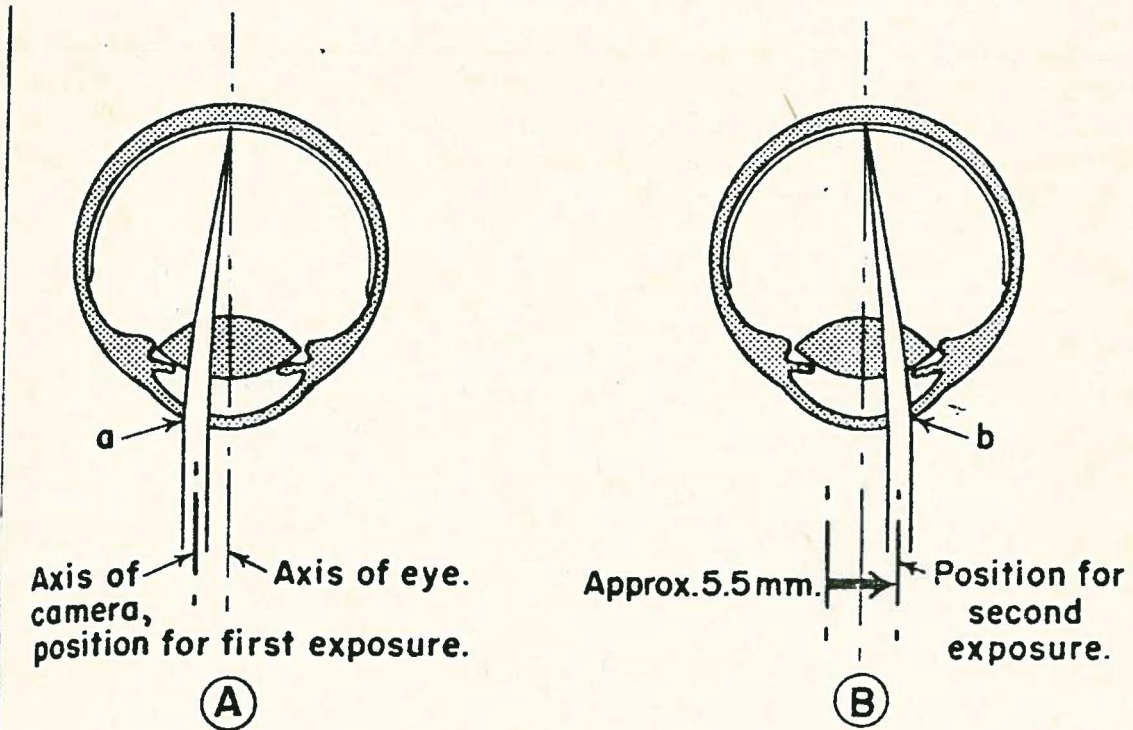


Fig. 7 (Allen). Principle of using cornea-induced parallax alone to take stereoscopic pictures of the fundus is diagrammed in horizontal cross section of subject eye. A, position and alignment of camera for taking left eye view; a, 2.0 mm. area through anterior segment through which picture emerges toward camera; B, position and alignment of camera for right eye view; b, area comparable to (a) but on opposite side of cornea and pupil. Black arrow indicates direction of shift of axis of camera.

Compare slides 389-390 which are photographs of toxoplasmosis scars taken in the hand held mode versus slides 33-34 which are photographs taken with the stand mount of the same target area. The camera was set at 2X magnification and the 2.7X oversert was used in all of these photos. Note the increased resolution and focusing of detail using the head stand mount.

Care must be taken to align the camera directly across from the pupil. A slight deviation can cause a large glare spot to appear in the photograph. To correct this simply re-align the camera up or down vertically to eliminate the glare.

STEREOSCOPIC PHOTOGRAPHY

Documentation of elevations and depressions in ocular photography requires a special approach to gain the depth perception needed for proper evaluation. The best method would involve simultaneous stereoscopic photography where two pictures are simultaneously taken of the ocular structure. This eliminates any positional changes which may occur if the photos are taken sequentially. The Kowa RC-2 is not capable of this type of stereoscopic shooting, and must instead rely on the corneal induced parallax method pioneered by Bedell in the late 1920's.⁵

In this method, two sequential photographs are taken keeping all the variables constant except lateral positioning of the camera. A lateral shift of 3.5 - 5.5mm.^{5,6,8} will give optimum stereopsis but any lateral shift will give some degree of depth. The camera should move in a parallel fashion to the target, instead of rotating along an arc which has the target as a center point. See figure 3 for illustration.

To view the slides, any Brewster type stereoscopic system may be used. An easy way is to use the stereoscopic glasses provided in the back cover of Clinical Ophthalmology. Hold the slides so the left slide fills the left lens and the right slide fills the right lens. This will necessarily overlap the slides by $\frac{1}{4}$ - $\frac{1}{2}$ " and bring them to about 4 - 5" from the stereo glasses. Although this method does not allow quantitative analysis, it provides a means for qualitative evaluation of fundus depth anomalies.

Slides 21 - 40 will give an appreciation of how stereoscopic photography can give an added dimension to ocular photography. Slides 25 - 26 demonstrate an elevated area adjacent to a vortex vein. Slides 33 - 34 demonstrate the depressed area along the rim of an old toxoplasmosis scar. Note in slides 37 - 38 and 433 - 434 that relative location of cataracts may be guesstimated using stereoscopic enhancement.

FLUORESCEIN PHOTOGRAPHY

The Kowa RC-2 is capable of taking fluorescein angiography with the proper attachments. For the purposes of the general optometric office, only external fluorescein photography need be addressed. The camera has a built-in blue exciter filter which can be drawn over the strobe flash. Also a yellow barrier disc is placed over the camera lens aperture.¹⁰ The combination effect will give adequate fluorescein enhancement for general adnexal photography. The Kodak #47A Wratten gelatin filter may be used as a replacement for the blue exciter filter and the Nikon Y48 medium yellow filter may be substituted for the yellow barrier disc.¹¹ Note how the use of

only the yellow barrier disc (slides 419 - 420) or the blue exciter filter (slides 283, 297) detracts from the fluorescence. Both must be used in combination to give the maximal effect.

Fluorescein photography can be used to document not only contact lens patterns (slides 221 - 223) but also to illustrate corneal ulcers. Slide 9 illustrates fluorescein leakage into the corneal stroma. This photo had no filters interposed and was taken as a normal adnexal photo. Punctate staining of the cornea is difficult to photograph unless it is fairly gross. To do this, the 2.7X magnification oversert should be used in conjunction with the filters.

SEQUENTIAL FUNDUS MAPPING

With widespread fundus changes, it becomes important to have a set of photographs which document the changes over the entire posterior pole. In diseases such as diabetes and hypertension this will allow comparison at a later date to detect fine changes in the retina. It is best to use high magnification for greater detail resolution in these cases.⁸ Using the 2X magnification will give this detail. Another use of sequential fundus mapping is to specifically pinpoint the location of external lesions. Slides 52 - 55 illustrate how a peripheral scar is mapped starting from the disc as a reference point.

When performing sequential fundus mapping, use landmarks such as the disc or macula as reference points. For more peripheral photographs, vessel patterns can be used. When completed, a collage of the fundus can be created which will permit future monitoring of the condition. Slides 56 - 60 demonstrate survey mapping. A good method to follow is illustrated in figure 4.⁶

FIGURE 4

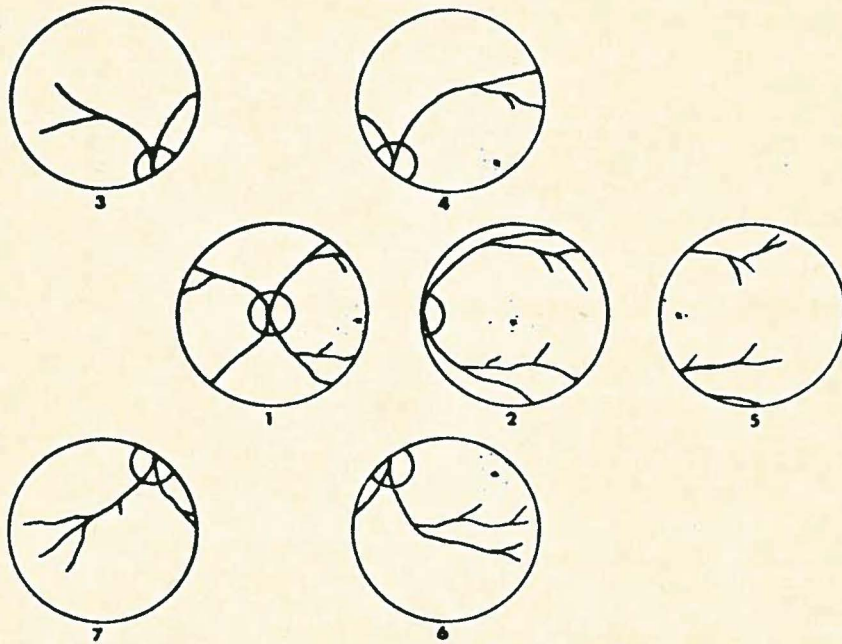


FIG. 12. Basic photographic mapping areas, each with a specific landmark (after Parr²⁰)

COMMON PHOTOGRAPHIC ERRORS

Photographic artifacts are frustrating and can ruin or distort ocular photodocumentation. With practice they can be recognized and eliminated thus helping to ensure consistent photographs. These artifacts can be classified into five basic types.^{5,6} Most of these errors are the result of improper camera distance and alignment. The operator will learn with practice approximately where the camera should be placed for each type of photograph. By carefully examining the film of view prior to exposure, he/she will be able to recognize and correct these misalignment and distance errors. Also, have good control of the patient's lids during fundus photography. This will eliminate artifacts caused by lid spasming and blinking. A summary of the five common artifacts, examples, and how to correct these is presented in table 2.

GUIDE FOR KOWA RC-2 OCULAR PHOTOGRAPHY

Each ocular structure has a specific combination of magnification, target/camera distance, and illumination which preferentially enhances that tissue's photodocumentation. These are not unvarying, however, and differences in pigmentation of the patient will affect these variables.

Table 3 is a good baseline for ocular photography using the Kowa RC-2. As a general rule, each anomaly should be photographed using a bracketing technique. This involves taking three or four shots of the structure at both higher and lower illumination levels. In this manner, three goals may be achieved. First, extra photographs are available which may be sent out with referral letters. Secondly,

this will allow stereoscopic interpretation and recording. Lastly, this becomes insurance against having only one poor photograph. Also, as a general rule, originals are diagnostically more valuable than duplicates of an original.

SUMMARY

The Kowa RC-2 camera has proved to be a useful aid in patient photodocumentation. Mobile, fairly inexpensive, and versatility in photography all are among the good points of the camera. It can be used to document most ocular anomalies and can be adapted to give approximately 5X magnification. The camera can also take fluorescein, stereoscopic and fundus survey photographs.

The major disadvantages are the need for dilation and the bright illuminating beam for viewing. Also, the technique of using the camera is at first difficult and can be frustrating.

The slides included with this paper are comprehensive and cover a variety of anomalies. None of the slides were discarded, so both the mistakes and successes are included. The first sixty slides compromise a good overview of the capabilities of the Kowa RC-2.

A follow-up study comparing this camera to the AO Docustar camera would be indicated. This new camera, which will be released over the summer of 1983, should eliminate some of the disadvantages inherent to the Kowa RC-2.