

"Clinical Use of a Hand Held +60D Lens
for Slit Lamp Funduscopy"

Senior Student: Ferris Standiford
Clinical Advisor: Victor Malinovsky O.D.

1985

'With most states now utilizing diagnostic pharmaceutical agents, it becomes necessary for the optometrist to sharpen his/her skills in diagnosing various ocular disorders. It is up to the optometrist to decide if a particular disorder is of a serious or nonprogressive nature, and the proper management that must be instituted.'¹ At present, there are two main clinical methods to obtain a highly magnified view of the ocular fundus, including Hruby lens examination, and use of the mirrored contact lens. A third technique, little known to many practitioners, uses a high plus powered aspheric lens (+60D) which provides an efficient, noncontact method to view the posterior pole and fundus periphery. Using the +60D lens in conjunction with the slit lamp, a highly magnified, stereoscopic, indirect view of the fundus is attainable with minimal preparation or discomfort to the patient. This paper will present both the positive and negative aspects of this technique, while comparing those features to that of Hruby lens and fundus contact lens examination. ~~It is hoped that the practitioner will gain insight into the clinical uses of the lens, while becoming familiar to the techniques involved in performing this type of indirect slit lamp ophthalmoscopy.~~

Historically, the use of a high powered lens in conjunction with a slit lamp was first described in the early 1950's. Since that time, various other examiners have described its use, but

with the absence of literature on this method, the procedure is little known to practitioners in the United States. Its popularity in other countries has gained rapidly in recent years due to its noncontact nature, good field of view, and ease of administration. 'In this procedure, a real, aerial image is produced between the examiner and the lens; the quality of this image is made distortion free by using an aspheric lens surface which greatly enhances the examiner's view.'² The earlier lenses used, when the procedure was first introduced, consisted of a plano-convex lens. This design resulted in much greater off axis distortion, thus obscuring the fundus view in the edges of the lens. In making our observations, a Volk +60D lens was used. This highly polished, biconvex, double aspheric lens has a diameter of 31 mm and is encased in a protective outer metal ring for easier handling. The lens comes in both clear glass and a yellow tint, which is aimed at decreasing reflections and the intensity of ultraviolet light entering the patient's eye, thus making it a safer and more comfortable procedure from the patient's standpoint.

Basically, fundus examination is accomplished by positioning the lens approximately 1.7 cm in front of the patient's eye, with the slight indentation of the outer metal ring following the patient's eyebrow line. The distance of 1.7 cm represents the focal distance of the lens. The lens is held with the thumb and index finger of the examiner's left hand when examining the patient's right eye. The examiner's right hand is then free to control the focusing with the slit lamp. Since a real, inverted image of the fundus will be produced 16-17 mm behind the supplementary lens

(+60D), it is necessary to situate the slit lamp in a more posterior position by pulling back on the joystick. To enhance initial viewing of the fundus, the observation and illumination axes should be aligned while the aperture setting is decreased to a 2 or 3 mm slit. The lowest magnification setting on the slit lamp should initially be employed. Since the lens is hand held, and not mounted in a stationary position, it can easily be maneuvered to eliminate reflections, increase clarity of the image, and maximize field of view. The remaining fingers on the hand holding the lens can be rested on the patient's orbital rim or brow bar of the slit lamp to help stabilize and position the lens in its best location.

Once a good clear view of the fundus is captured, there are various conditions which can be altered to enhance viewing. Starting with a 2 or 3 mm slit, the width of the beam can be increased to its maximum aperture size; our experience indicated this often resulted in annoying reflections off the lens surface, and an uncomfortable patient who responded with a blepharospasm. Therefore, the aperture setting can be manipulated until the best view, either direct or indirect, is captured. 'By slightly altering the angle between the illumination and observation axes of the slit lamp, the stereoscopic view of the fundus can be maximized. This effect is further described in an article by Hans Rotter.³ With the use of a fixation light in front of the non-examined eye, the patient's direction of gaze and fixation can easily be controlled. To view parts of the fundus periphery, it is also possible to have the patient make extreme lateral or vertical eye movements, or just rotate the patient's head in the desired direction. It must also

be remembered that due to the optics of the system, the image viewed by the examiner is inverted and reversed, as in performing binocular indirect ophthalmoscopy. Therefore, nasal retina will appear temporally in the lens and superior retina will appear as being inferior in location.

In using the +60D lens, a maximally dilated pupil was used in all patients examined. This not only maximizes field of view, but is necessary to ensure stereopsis since the illumination and observation axes must travel through separate areas of the pupil. 'When using a nondilated pupil, at best a monocular view of the disc can be obtained, with the intense illumination producing a further miotic pupil.'⁴ Hans Rotter, however, states that "in cases of pupils that cannot be dilated to the utmost, the stereoscopic accessibility of the fundus can be obtained with the observation in the horizontal optical section rather than with observation in the sagittal one."⁵ We found viewing through a non-dilated pupil a difficult task, and feel the best benefit of the lens is achieved by using a maximally dilated pupil. For each of the patients examined, the three methods of fundus observation were performed, and various qualities of each procedure were compared as follows: field of view, magnification, ease of performance, patient acceptance, clarity of image, and other factors.

Field of view ranges from being very small using a Hruby lens, moderately large using a fundus lens, and large with the +60D lens. As indicated in Table A, we measured the approximate field of view, in disc diameters, of the three methods. At 6x magnification on the slit lamp, the Hruby lens had a field of 2DD, the fundus lens was 3-4DD, while the +60D lens had a field of up to 8DD.

It should be noted that in using the +60D lens, a fully open aperture setting on the slit lamp will not completely fill the surface area of the lens, thus resulting in an illuminated field of about 5DD. The remaining 3DD can be obtained by simply moving the light source either horizontally or vertically towards the edge of the aspheric lens. The +60D lens allows a good simultaneous view of the disc and macula even when the light source is not open to its widest setting. As noted earlier, the fundus periphery out to the equator or further can be observed by decentering the lens and having the patient change their fixation.

"The magnification attained with the plus lens is much greater than with the Hruby lens. In the use of the Hruby lens it is necessary to examine usually with the highest power available, while with the +60D lens it is best to start with the lowest power of the microscope."⁶ We also noted the magnification of the +60D lens to be greater than that of the fundus lens. The final magnification achieved in all methods is dependant on the various magnification settings available on the slit lamp. While using the +60D lens and switching to a higher magnification, it is necessary for the patient to hold fixation steady in order to obtain an acceptable level of fundus resolution. Also, movements of the examiner's hand may result in a momentary loss of fundus detail. These factors are not as critical when using a Hruby lens or fundus lens, since the optics of these systems are more stable in relation to the patient's eye.

In considering ease of performance, Hruby lens and +60D lens examination are relatively simple procedures. They require no

preliminary preparation, other than inducing a widely dilated pupil. Fundus lens examination, on the other hand, requires more preparation and is a more difficult procedure to perform for an examiner unfamiliar with it. A dilated pupil, corneal anesthetic, and cooperative patient are necessary to efficiently use the fundus lens. Using a three mirrored Goldman lens, an excellent view of the posterior pole, equator, fundus periphery, and anterior chamber angle can be obtained making this lens a highly valuable diagnostic tool.

With the +60D lens and Hruby lens being noncontact methods, patient acceptance is very good and they are both excellent procedures for general clinical application. At times, the intense illumination can make the patient somewhat uncomfortable. 'The fundus lens has a more limited clinical application and is certainly contraindicated in various postoperative or infected eyes. It may also be difficult to perform on children or apprehensive patients, and can produce a keratitis in some patients.'

The quality of the image obtained when examining a particular fundus anomaly is very important when attempting to make the proper diagnosis. Fluctuations in image clarity, or loss of stereopsis are annoying factors when performing an exam. Overall, the fundus lens provides probably the best fundus resolution, with the least fluctuations in image clarity. This is due to the stability of the lens-eye relationship produced by the gonioscopic gel used in the procedure. Hruby lens examination also provides an excellent stereo view of the disc or macula, but a patient with unsteady fixation makes this more difficult. Finally, the +60D lens is

capable of producing a highly resolved, magnified, and stereoscopic view of the fundus; however, the inherent nature of movements of the examiner's hand holding the lens or movements of the patient's eye can produce a momentarily blurred image or loss of stereopsis. Greater familiarity with the use of the lens greatly reduces these problems.

The optics of the various methods are shown in the diagrams included. Basically, the fundus lens eliminates the refractive power of the cornea allowing direct observation of the fundus with the slit lamp. The Hruby lens has a power of about -58D and in a sense also nullifies the refractive power of the eye. In this case, a virtual image is formed at the focal point of the lens, which is near the cornea. The +60D lens reconverges light rays exciting the eye and focuses them at its secondary focal point. The image is real and inverted, and lies about 1.7 cm in front of the lens (between the lens and the examiner). Therefore, for its image to be viewed, the slit lamp must be moved to a more posterior position as mentioned previously.

From a clinical standpoint, use of the +60D lens seems to have an excellent application not only for diagnosis of ocular pathology, but in routine fundus examination. Because the lens provides a large field of view, high magnification, and stereopsis, it makes a valuable tool for the clinician to perform on most all patients. Furthermore, the minimal preparation involved allows the procedure to be done rapidly and efficiently. Following is a short list of some of the uses of the +60D lens:

- A. Optic Nerve
 - 1. nerve head cupping
 - 2. papilledema
 - 3. buried drusen
 - 4. papillitis

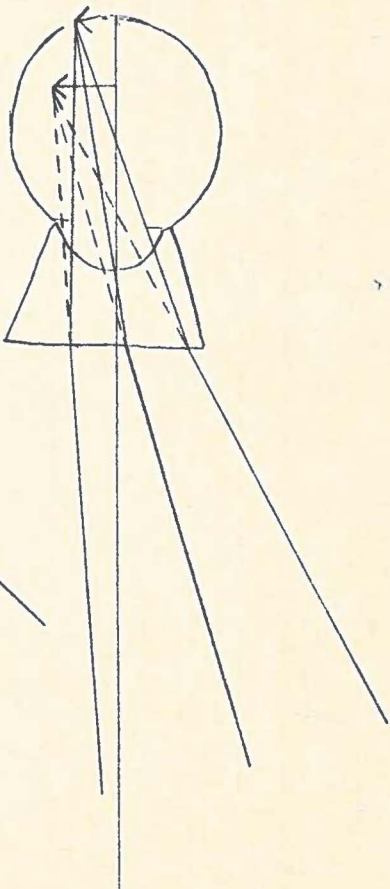
- B. Retina
 - 1. holes vs. cysts
 - 2. arteriosclerotic changes
 - 3. diabetic retinopathy signs
 - 4. nevi vs. melanomas

- C. Vitreous
 - 1. PVD
 - 2. liquefaction

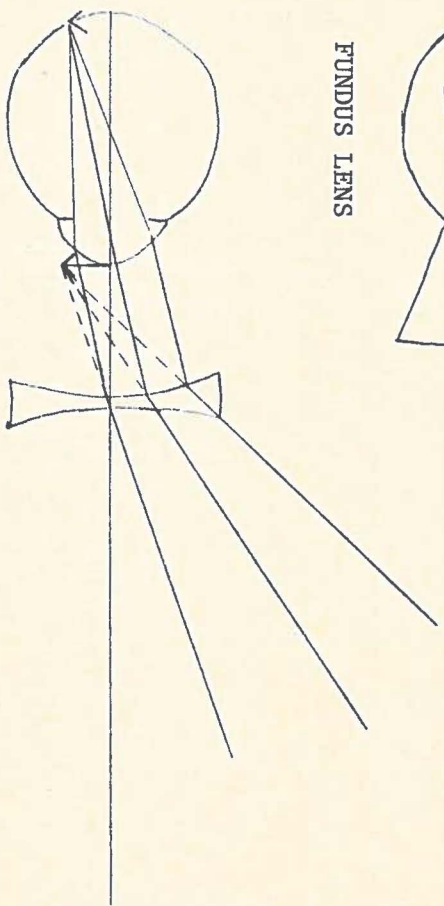
Disadvantages noted during use of the +60D lens include a decrease in resolution of the image with changes in lens position, and a difficult time holding up the patient's upper lid when there is excessive sensitivity to the light. This is due to the fact that there is not a free hand to control the upper lid as in Hruby lens examination. The article by H. Rotter states the use of a lens holder mounted on the slit lamp where either a concave (Hruby) lens or convex lens can be mounted into it. We consider it to be of greater benefit when the +60D lens is hand held to aid in scanning of peripheral areas of the fundus, and to eliminate reflections off the lens surface. Overall, the benefits that the hand held +60D lens offers to the clinician are numerous and it is hoped that further knowledge, interest, and use of the lens will be gained by more practitioners in the United States.

	<u>+ 60 D</u>	<u>HRUBY</u>	<u>FUNDUS LENS</u>
FIELD OF VIEW (AT 6X Mag.)	Approx. 7 DD	Approx. 2 DD	Approx. 3½ DD
MAGNIFICATION	Variable with slit lamp (Greater than Hruby)	Variable with slit lamp (Best to use high mag.)	Variable with slit lamp
EASE OF USE	Good, once familiar with procedure	Good, once familiar with procedure	Requires greater examiner experience
PATIENT PREPARATION	Minimal (Dilation preferred)	Minimal (Dilation necessary)	Anesthetic required
PATIENT COMFORT	Good with lower light intensity	Can be uncomfortable with intense illum.	Minimal to very uncomfortable Can result in keratiti
CLINICAL APPLICATION	Excellent	Excellent	Limited

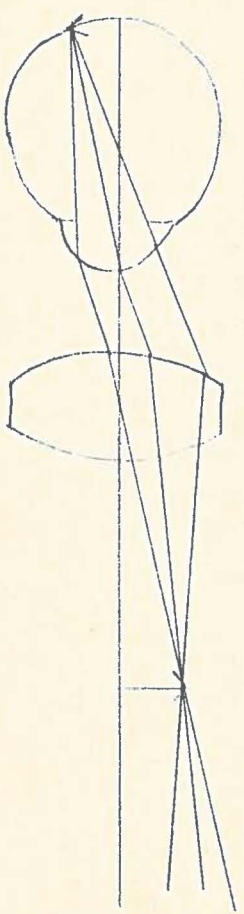
TABLE A



FUNDUS LENS



HRUBY LENS



+ 60 D LENS

ENDNOTES

1. Bock, William C., "Fundus Contact Lens and Hruby Lens," J. of the Amer Opt. Assoc., Vol. 48, No. 11, p. 1425, Nov. 1977.
2. Lundberg, Claes, "Biomicroscopic Examination of the Ocular Fundus with a +60 D Lens," p. 3.
3. Rotter, H., "Technique of Biomicroscopy of the Posterior Eye," Am. J. of Ophthal., Vol. 42, p. 409, 1956.
4. Lundberg, Claes, "Biom. Ex. of the Oc. Fund. with a +60 D Lens," p. 4.
5. Rotter, H., "Tech. of Biom. of the Post. Eye," Am. J. of Ophthal., Vol. 42, p. 411, 1956.
6. Rosen, E., "Biomicroscopic Examination of the Fundus with a +55 D Lens," Vol. 48, p. 785, 1959.
7. Lundberg, Claes, "Biom. Ex. of the Oc. Fund. with a +60 D Lens," p. 4.

BIBLIOGRAPHY

- Bock, William C., Fundus Contact Lens and Hruby Lens, J. of the Amer. Opt. Assoc., 48: pp. 1425-29, Nov. 1977.
- Ei Bayadi, George, New Method of Slit-Lamp Micro-Ophthalmoscopy, British J. of Ophthal., 37: pp. 625-8, 1953.
- Kajiura, M., Hashimoto, H., Takahashi, F., Use of Aspherical Convex Lens for Slit Lamp Funduscopy, Japanese J. of Clinical Ophthal., 31: pp.1399-403, 1977.
- Lundberg, Claes, M.D., Biomicroscopic Examination of the Ocular Fundus with a +60D Lens, pp. 1-5.
- Rosen, E., Biomicroscopic Examination of the Fundus with a +55D Lens, Amer. J. of Ophthal., 48: pp. 782-7, 1959.
- Rotter, H., Technique of Biomicroscopy of the Posterior Eye, Amer. J. of Ophthal., 42: pp. 409-15, 1956.